



MEDITVETJ

MAKÜ

JUNE

2024

VOLUME 9

ISSUE 1

MEDITERRANEAN
VETERINARY JOURNAL

Mediterranean Veterinary Journal

Volume: 09 . Number: 01 . 2024

Published tri-annual

Former name

Veterinary Journal of Mehmet Akif Ersoy

University

Publisher

On behalf of Budur Mehmet Akif Ersoy University

Faculty of Veterinary Medicine

Prof. Dr. Hüseyin DALGAR

Rector

Editorial Board

Editor-in Chief

Prof. Dr. Mehmet Çağrı KARAKURUM

Editors

Prof. Dr. Zafer ÖZYILDIZ

Prof. Dr. Ahmet AYDOĞAN

Assoc. Prof. Dr. Ömer Gürkan DİLEK

Assoc. Prof. Dr. Umair AHSAN

Language Editor

Prof. Dr. Ahmet AYDOĞAN

Assoc. Prof. Dr. Umair AHSAN

Secretary

Asst. Prof. Dr. Derya Merve KARAGÖZ

Layout, Page Design and Composition

Ozan KOÇLU

Tel: 0248 213 2000/2010

Address

Burdur Mehmet Akif Ersoy Üniversitesi

Faculty of Veterinary Medicine

Degirmenler, 15030, BURDUR

Publication Board

Prof. Dr. Özlem ÖZMEN, Burdur Mehmet Akif Ersoy Üniversitesi,
Burdur, Türkiye

Dr. Aaron Aykut Uner, Harvard Medical School, Boston, MA, USA

Prof. Dr. Zafer ÖZYILDIZ Burdur Mehmet Akif Ersoy Üniversitesi,
Burdur, Türkiye

Prof. Dr. Ahmet AYDOĞAN, Çukurova Üniversitesi, Adana, Türkiye

Dr. Ömer Gürkan DİLEK, Burdur Mehmet Akif Ersoy Üniversitesi,
Burdur, Türkiye

Prof. Dr. Ramazan ADANIR, Burdur Mehmet Akif Ersoy Üniversitesi,
Burdur, Türkiye

Dr. Mikas BALKEVICIUS, Ngo - Problem Based of Learning Institute,
Vilnius, Lithuania

Dr. Seyda CENGİZ, Atatürk Üniversitesi, Erzurum, Türkiye

Prof. Dr. Rosen DIMITROV, Trakia University, Stara Zagora, Bulgaria

Dr. Aldona MIGALA-WARCHOL, University Of Technology, Poland

Dr. Sokol DURO, Agricultural University of Tirana, Albania

Dr. Iwona OTROCKA-DOMAGALA, University of Warmia And
Mazury in Olsztyn, Poland

Dr. Kamelia STAMATOVA-YOVCHEVA, Trakia University, Stara
Zagora, Bulgaria

Prof. Dr. Şule Yurdağül ÖZSOY, Aydın Adnan Menderes Üniversitesi ,
Aydın, Türkiye

Dr. Hidayet TUTUN, Burdur Mehmet Akif Ersoy Üniversitesi, Burdur,
Türkiye

Dr. Harun ÇINAR, Burdur Mehmet Akif Ersoy Üniversitesi, Burdur,
Türkiye

Advisory Board

Prof. Dr. Özlem ÖZMEN, Burdur Mehmet Akif Ersoy Üniversitesi,
Burdur, Türkiye

Prof. Dr. Zafer ÖZYILDIZ, Burdur Mehmet Akif Ersoy Üniversitesi,
Burdur, Türkiye

‘This Journal is indexed and abstracted by TUBİTAK-ULAKBİM TR-Dizin, Zoological Record, EBSCO, CAB Abstract, CiteFactor, Google Scholar,
Science Library Index, International Institute of Organized Research, Researchbib, SciLit, SJIFactor, COSMOS IF and SOBIAD.’

All rights are reserved. All of this publication’s scientific studies, or part or all of them, are published in the journal Burdur Mehmet Akif Ersoy University.

It cannot be copied or published by any electronic, mechanical, photocopying, or other recording method without the prior consent of the Dean of the
Faculty of Veterinary Medicine.

E-mail: veterinerdergi@mehmetakif.edu.tr

Web Address: <https://edergi.mehmetakif.edu.tr/index.php/vfd>

Online Submission

<http://dergipark.gov.tr/journal/779/dash-board>

The iThenticate/Turnitin plagiarism analysis program is used to check submitted articles for originality before they are accepted for publication.

The reviewers of MEDIVETJ, 2024, 9 (1)

ALTAN Semih, *Dokuz Eylül University, Faculty, Veterinary Medicine*
CEYLAN Ebubekir, *Ankara University, Faculty of Veterinary Medicine*
ÇEVİK Mesut, *Ondokuz Mayıs University, Faculty of Veterinary Medicine*
ÇİZMECİ Sakine Ülküm, *Selçuk University, Faculty of Veterinary Medicine*
ERGİN İrem, *Ankara University, Faculty of Veterinary Medicine*
GÖLGELİ BEDİR Ayşe, *Atatürk University, Faculty of Veterinary Medicine*
KARAPINAR Zeynep, *Balıkesir University, Faculty of Veterinary Medicine*
KELEŞ İhsan, *Erciyes University, Faculty of Veterinary Medicine*
MİS Leyla, *Van Yüzüncü Yıl University, Faculty of Veterinary Medicine*
ORHUN Ömer Tarık, *Atatürk University, Faculty of Veterinary Medicine*
OZAN Emre, *Ondokuz Mayıs University, Faculty of Veterinary Medicine*
ÖNYAY Taylan, *Ondokuz Mayıs University, Faculty of Veterinary Medicine*
PARLAK Kurtuluş, *Selçuk University, Faculty of Veterinary Medicine*
SEYİDOĞLU Nilay, *Tekirdag Namik Kemal University, Faculty of Veterinary Medicine*
TİMURKAN Mehmet Özkan, *Atatürk University, Faculty of Veterinary Medicine*

*Volume 9, Issue 1 of 2024 has an alphabetical list of the editorial board and reviewers.

CONTENTS

Research Articles

Evaluation of iron, iron binding capacity, transferrin, some oxidative stress markers and hematological parameters in foot and mouth disease in cattle	
SEZER M, GEZER T, MERHAN O, AKYUZ E, BOZUKLUHAN K, GOKCE G.....	224-229
Evaluation of neuroophthalmologic examination in cats and dogs: A retrospective study: 110 cases (2023)	
ŞENGÖZ ŞİRİN Ö, ŞİRİN MY, ELVAN AN.....	230-235
Incidence of hoof deformities in honamli herd raised semi-intensively	
ÇINAR H, ŞİRİN MY.....	236-239
Effect of seminal plasma treatment on conception rate in ovsynch treated holstein cows	
BAŞTAN İ, ÇETİN Y.....	240-246
The effects of exercise on vascular responses in rats with type 1 diabetes	
CAN Z, ÜNSAL C.....	247-253
Molecular detection of deformed wing virus, black queen cell virus in honey bees in balıkesir province	
KARAPINAR Z, ÖZÜÇLİ M.....	254-260
Molecular detection of feline calicivirus (FCV) in cats with oral le	
SALTIK HS, ERDAĞI Z.....	260-265

Case reports

Right aortic arch with megaesophagus in a jack russel dog and diagnosis with contrast fluoroscopy	
ŞİRİN YS, ŞİRİN MY, ÇETİN MN.....	219-223

Evaluation of iron, iron binding capacity, transferrin, some oxidative stress markers and hematological parameters in foot and mouth disease in cattle

Mert Sezer¹, Tahir Gezer¹, Oguz Merhan², Enes Akyuz¹, Kadir Bozukluhan¹, Gurbuz Gokce¹

¹Department of Internal Medicine, Faculty of Veterinary Medicine, Kafkas University, Kars, Türkiye

²Department of Biochemistry, Faculty of Veterinary Medicine, Kafkas University, Kars, Türkiye

Key Words:

cattle
foot and mouth disease
oxidative stress
transferrin

Received : 31 May 2023
Revised : 15 December 2023
Accepted : 13 February 2024
Published : 12 June 2024
Article Code : 1307672

Correspondence:

M. SEZER
(sezermert100@gmail.com)

ORCID

M. SEZER : 0000-0003-1691-7764
T. GEZER : 0000-0001-7838-2553
O. MERHAN : 0000-0002-3399-0667
E. AKYUZ : 0000-0002-3288-2058
K. BOZUKLUHAN : 0000-0003-4929-5156
G. GOKCE : 0000-0002-2492-5193

The abstract of this manuscript was presented as a poster presentation at the 14th National 3rd International Veterinary Internal Medicine Congress.

ABSTRACT

This study aimed to investigate the changes in serum iron, iron binding capacity, transferrin, some oxidative stress markers, and hematological and biochemical parameters in cattle infected with foot-and-mouth disease and to reveal their importance. The animal material of the study was composed of 20 Simmental cattle between 6 and 12 months of age, which were diagnosed with foot-and-mouth disease based on the results of the clinical and laboratory examinations (patient group), and the control group was composed of 10 animals selected from a different herd, with the same age group and breed characteristics and fed with the same ration. Among the hematological parameters examined in the study, the total leukocyte count (WBC (x103/ μ L)) was found to be higher in the patient group with statistical significance compared to the control group ($P < 0.05$). Among the biochemical parameters, iron (Fe (μ g/dL)), total iron binding capacity (TIBC (μ g/dL)), phosphorus (P (mg/dL)), magnesium (Mg (mg/dL)), and glucose (mg/dL) levels were found to be significantly lower ($P < 0.001$); the transferrin saturation (TS (%)), reduced glutathione (GSH (mg/dL)), and alkaline phosphatase (ALP (U/L)) were found to be significantly lower ($P < 0.05$); and Malondialdehyde (MDA (μ mol/L)), creatine kinase (CK (U/L)), and creatinine (Crea (mg/dL)) were found to be significantly higher ($P < 0.05$) in the patient group compared to the control group. Consequently among the biochemical parameters examined in the study, the changes in the Fe (μ g/dL), TIBC (μ g/dL), TS (%), GSH (mg/dL), and MDA (μ mol/L) levels were observed.

INTRODUCTION

Foot and Mouth Disease (FMD) is a contagious vesicular disease (Wong et al., 2020). It is a highly contagious viral disease that affects ungulates in particular (Gökce et al., 2004). The morbidity rate of the disease is 100% among susceptible animals and between 80-100% among the offspring (Gakuya et al., 2011). The agent that causes the disease is Aphthovirus, a single-stranded RNA virus from the Picornaviridae family (Gokce et al., 2004). The agent has 7 main stereotypes, which are O, A, C, SAT 1, SAT 2, SAT 3, and Asia 1, and these stereotypes have various subtypes (more than 60 strains) (Uzlu et al., 2016; Wong et al., 2020).

Serum Fe concentration is considered an inflammatory biomarker in domestic animals, and iron metabolism is impaired in many systemic diseases (Gozzelino and Arosio, 2016). Transferrin (Tf) is an important protein for the binding and transfer of iron (Gomme et al., 2005). Transferrin is a negative acute-phase protein; therefore, it decreases in inflammatory cases (Asif et al., 2016).

Iron binding capacity is an important test used in the diagnosis of iron metabolism disorders and is defined as the iron binding capacity of transferrin. There are two types of

iron-binding capacity: total iron-binding capacity (TIBC) and unsaturated iron-binding capacity (UIBC). Transferrin saturation (TS) is expressed as a percentage and indicates the amount of serum Fe bound to Tf (Elsayed et al., 2016).

The pathogenesis of many diseases involves oxidative stress. Oxidative stress develops due to the impairment of the balance between oxidants and antioxidants (Ozcan et al., 2015) and leads to cellular damage (Marreiro et al., 2017). The activation of protective antioxidant defense mechanisms in cells with the stimulation of lipid peroxidation causes some changes in malondialdehyde (MDA) and reduced glutathione (GSH) levels (Uzlu et al., 2016). For this reason, reduced glutathione (GSH) and malondialdehyde (MDA) concentrations are measured to determine oxidative stress in diseases (Uzlu et al., 2016; Bozukluhan et al., 2021).

This study aimed to investigate the changes in iron, total iron-binding capacity, transferrin saturation, some oxidative stress markers, and hematological parameters in foot and mouth disease in cattle and reveal their importance.

MATERIALS and METHODS

This study was initiated after obtaining approval from the Kafkas University Local Ethics Committee of Animal Exper-

iments (KAU-HADYEK/2022-032) and the Kars Provincial Directorate of Agriculture.

Animal material

The animal material of this study was composed of 20 Simmental cattle between 6-12 months of age, which were raised in the villages of Kars where FMD was diagnosed by the Kars Provincial Directorate of Agriculture and showed FMD symptoms (patient group), and the control group was composed of 10 animals selected from a different herd, with the same age group and breed characteristics and fed with the same ration. The clinical examinations were performed on the animals in the patient and control groups, and the T (rectal body temperature (°C)), P (pulsation (n/min)), and R (respiration (n/min)) counts were noted.

Taking blood samples

Blood samples were obtained from the infected cattle before treatment (hour 0) and from healthy cattle once, using a holder and compatible sterile needle tip (Vacuette®, Greiner Bio-One GmbH, Austria) into vacuum gel serum tubes (BD Vacutainer®, BD, UK) and vacuum EDTA blood tubes (BD Vacutainer®, BD, UK). Serum samples were obtained by centrifuging the blood samples in vacuum tubes at 3000 rpm for 10 minutes (Hettich Rotina 380R®, Hettich, Germany).

Biochemical and hematological measurements

Total leukocyte count (WBC $\times 10^3/\mu\text{L}$), erythrocyte count (RBC $\times 10^6/\mu\text{L}$), percentage of hematocrit (Hct %), hemoglobin concentration (Hb g/dL), and platelet count (Thr $\times 10^3/\mu\text{L}$) were measured from whole blood samples using a complete blood count device (VG-MS4e®, Melet Schloesing, France). Alanine aminotransferase [ALT (IU/L)], aspartate aminotransferase [AST (IU/L)], glucose (mg/dL), creatinine [CREA (mg/dL)], urea [UREA (mg/dL)], total protein [TP (g/dL)], lipase (U/L), creatine kinase [CK (IU/L)], calcium [Ca (mg/dl)], phosphorus [P (mg/dl)], magnesium [Mg (mg/dl)], amylase ((U/L), 25-Hydroxy Vitamin D (ug/L), gamma-glutamyl transferase [GGT (U/L)], alkaline phosphatase [ALP

(U/L)], and total bilirubin [TBIL (mg/dl)] enzyme activities were measured in the serum samples using a fully automatic biochemistry device (Mindray BS120®, Mindray Medikal Teknoloji Istanbul, Turkiye).

Malondialdehyde (MDA) was measured according to the method reported by Yoshiko et al., (1979), and reduced glutathione (GSH) was measured according to the method reported by Beutler et al., (1963). Iron (Fe) and unsaturated iron binding capacity (UIBC) were measured with a commercial testing kit (Biolabo, France) colorimetrically (Epoch, Biotek, USA). Total iron binding capacity (TIBC) was obtained by adding serum iron (Fe) and unsaturated iron binding capacity (UIBC) levels. Serum transferrin saturation (TS) was calculated over serum Fe and TIBC levels using the formula $[\text{TS} (\%) = \text{Fe} / \text{TIBC} \times 100]$ (Merhan and Ozcan, 2010).

Statistical analysis

Statistical data were analyzed using the SPSS® (SPSS 26.0, Chicago, IL, USA) software. The statistical differences between the groups with normal distribution according to the Shapiro-Wilk test were compared with the independent sample t-test. The obtained results were given as mean \pm standard error of the mean (SEM). $P < 0.05$ was considered statistically significant in the evaluation of the results.

RESULTS

In the clinical examination of the cattle included in the study, symptoms such as anorexia, excessive salivation, weight loss, high fever, vesicular lesions in the foot and mouth mucosa, lameness, and nail shedding were observed. The rectal body temperatures (°C), pulsation (n/min), and respiration (n/min) counts of the infected and healthy cattle were evaluated and presented in Table 1. Among the vital parameters, body temperature and respiratory rate were determined to be higher in the patient group with statistical significance compared to the control group ($P < 0.05$). There was no statistically significant difference between the patient and control groups in terms of pulsation rate ($P > 0.05$). Hematological results of the infected and healthy cattle were presented in Table 1. Among the hema-

Table 1. Mean and standard error values of hematological and vital signs in patient and control cattle.

Parameters	Patient (n: 20)	Control (n: 10)	P
	Mean \pm SEM	Mean \pm SEM	
WBC ($\times 10^3/\mu\text{L}$)	14.32 \pm 1.00	7.71 \pm 0.37	<0.001
RBC ($\times 10^6/\mu\text{L}$)	9.42 \pm 0.49	8.64 \pm 0.23	0.160
HCT (%)	35.70 \pm 1.46	31.31 \pm 1.89	0.085
Hb (g/dl)	9.68 \pm 0.37	10.73 \pm 0.43	0.095
THR ($\times 10^3/\mu\text{L}$)	504.50 \pm 25.34	416.60 \pm 63.88	0.225
T (°C)	39.59 \pm 0.19	38.68 \pm 0.20	0.006
P (sayı/dk)	81.00 \pm 3.61	68.60 \pm 7.51	0.102
R (sayı/dk)	34.40 \pm 2.65	24.50 \pm 2.46	0.024

WBC: Total leukocyte count, RBC: Erythrocyte count, HCT: Hematocrit, Hb: Hemoglobin, THR: Platelet count, T: Rectal temperature, P: Heart beats/min, R: Breaths/min. $P < 0.05$ indicates statistical significance. SEM: Standard error of mean.

Table 2. Mean and standard error values of biochemical findings in patient and control cattle.

Parameters	Patient (n: 20)	Control (n: 10)	P
	Mean \pm SEM	Mean \pm SEM	
Fe ($\mu\text{g/dL}$)	78.91 \pm 1.85	99.72 \pm 3.10	<0.001
TIBC ($\mu\text{g/dL}$)	212.62 \pm 3.06	237.28 \pm 3.95	<0.001
TS (%)	37.34 \pm 1.16	42.08 \pm 1.33	0.018
MDA ($\mu\text{mol/L}$)	3.70 \pm 0.19	2.52 \pm 0.14	<0.001
GSH (mg/dL)	52.32 \pm 2.90	64.34 \pm 3.47	0.018
Lipase (U/L)	30.70 \pm 0.60	29.26 \pm 0.74	0.161
Ca (mg/dl)	8.90 \pm 0.12	8.14 \pm 1.04	0.484
P (mg/dl)	5.82 \pm 0.34	7.94 \pm 0.22	<0.001
Mg (mg/dl)	1.81 \pm 0.07	2.22 \pm 0.05	<0.001
Amylase (U/L)	26.40 \pm 1.97	28.70 \pm 1.98	0.469
25-Hydroxy Vitamin D (ug/L)	35.53 \pm 3.71	31.91 \pm 2.98	0.529
ALT (U/L)	30.88 \pm 4.48	31.22 \pm 5.46	0.963
AST (U/L)	92.28 \pm 8.03	95.79 \pm 9.52	0.792
GGT (U/L)	21.28 \pm 1.79	20.54 \pm 1.17	0.784
ALP (U/L)	115.90 \pm 8.64	186.98 \pm 30.15	0.046
CREA (mg/dl)	1.55 \pm 0.14	0.91 \pm 0.05	<0.001
UREA (mg/dl)	105.24 \pm 3.98	118.87 \pm 5.33	0.054
TBIL (mg/dl)	0.35 \pm 0.15	0.11 \pm 0.03	0.289
TP (gr/dl)	6.86 \pm 0.25	6.31 \pm 0.31	0.203
CK (U/L)	553.16 \pm 112.61	279.32 \pm 38.29	0.031
Glucose (mg/dl)	41.40 \pm 2.65	98.10 \pm 5.82	<0.001

Fe: Iron, TIBC: Total iron binding capacity, TS: Transferrin saturation, MDA: Malondialdehyde, GSH: Reduced glutathione, Ca: Calcium, P: Phosphorus, Mg: Magnesium, ALT: Alanine aminotransferase, AST: Aspartate aminotransferase, GGT: Gamma glutamyl transferase ALP: Alkaline phosphatase, Crea: Creatinine, UREA: Urea, TBIL: Total bilirubin, TP: Total protein, CK: Creatine kinase. P<0.05 indicates statistical significance. SEM: Standard error of mean.

tological parameters, WBC ($\times 10^3/\mu\text{L}$) was found to be higher in the patient group with statistical significance compared to the control group ($P<0.05$). In addition, no statistically significant difference was found between the patient and control groups in other hematological parameters ($P>0.05$). Biochemical values of the infected and healthy cattle were presented in Table 2. Among the biochemical parameters, the Fe ($\mu\text{g/dL}$), TIBC ($\mu\text{g/dL}$), P (mg/dl), Mg (mg/dl), and glucose (mg/dl) levels were lower with statistical significance ($P<0.001$) while TS (%), GSH (mg/dL), and ALP (U/L) were found to be significantly lower ($P<0.05$) in the patient group compared to the control group. In addition, MDA ($\mu\text{mol/L}$), CK (U/L), and Crea (mg/dl) were determined to be significantly higher in the patient group compared to the control group. ($P<0.05$). Despite the presence of differences between the patient and control groups, no statistically significant difference was found in lipase (U/L), Ca (mg/dl), amylase (U/L), 25-Hydroxy Vitamin D (ug/L), ALT (U/L), AST (U/L), GGT (U/L), UREA (mg/dl), TBIL (mg/dl), and TP (gr/dl) levels ($P>0.05$).

DISCUSSION

Clinical findings of the disease include high fever, tachypnea, and vesicular lesions in foot and mouth mucosa and various parts of the body, loss of weight, anorexia, excessive salivation, lameness, nail shed due to lesions in the feet are common in infected animals (Gakuya et al., 2011, Uzlu et al., 2016). Similar symptoms were observed during the clinical examination of the infected cattle in the present study.

In living beings, an acute phase response occurs in tumoral and immunological diseases due to inflammation and tissue damage related to infection. This response leads to local reactions, and the defense cells are activated (Yilmaz and Gokce 2017). Consequently, WBC increases (Yilmaz and Gokce 2017, Akyuz et al., 2022a). In this study, we observed that WBC was significantly higher in the patient group compared to the control group. We think that the increased number of WBCs in animals infected with FMD was a reaction of the immune system against severe inflammation and tissue damage, which occurred in many systems due to primary and secondary pathogenic factors. However, there are also studies stating that WBC does not change in FMD disease (Kar et al., 2015).

Iron has important roles as the building block of many proteins in the body, especially hemoglobin (Tapiero et al., 2001). Fe metabolism is affected by many pathological conditions such as inflammation, anemia, and renal failure that develop in living beings for various reasons (Baydar and Dabak 2014). There is a direct correlation between the incidence of diseases and Fe deficiency. Therefore, the level of Fe is frequently examined in the evaluation of inflammatory conditions. Fe level decreases rapidly in cases of severe inflammation and endotoxemia (Tsukano et al., 2020). The most important reason for the decrease in Fe level is the increased use of it by pathogenic agents (Ganz and Nemeth, 2009). In addition, the disruption of the enzyme activities that involve defense cells (Tapiero et al., 2001) and hypoferrremia mediated by interleukin-6 (IL-6) are considered to be responsible (Ganz and Nemeth, 2009).

In this study, the total iron binding capacity was low ($P < 0.001$) in the patient group. It was reported to be caused by the decrease in total iron binding capacity in cases of severe disease (Asif et al., 2016).

Transferrin saturation indicates the amount of serum Fe bound to transferrin. The most important reason for the decreased transferrin saturation is iron deficiency. The low level of iron in the blood indicates the use of a smaller transferrin binding area and low saturation in these binding areas (Elsayed et al., 2016). In this study, serum transferrin saturation was found to be lower in the patient group compared to the control group. The possible reason for this is the increase in the use of Fe by the pathogenic agents due to the severe course of the disease in animals with foot and mouth disease and the decrease in serum iron levels due to nutritional deficiency.

Stress factors and pathogenic agents, which play an important role in the pathogenesis of diseases, lead to an increase in the production of free radicals, weakening the antioxidant defense capacity and causing oxidative stress (Talukder et al., 2015). Lipid peroxidation is an indicator of oxidative stress that causes impairment in the structure and function of cells. Malondialdehyde (MDA), which originates from polyunsaturated fatty acids and is one of the decomposition products of lipid peroxides, is a parameter used for detecting both the degree of cellular damage (Sezer and Keskin 2014) and oxidative stress (Khoshvaghti et al., 2014). There is an increase, particularly in the MDA level under oxidative stress (Akyuz et al., 2021). Oxidative stress plays a role in the pathogenesis of many diseases, including foot and mouth disease (Uzlu et al., 2016). It was believed that the serum MDA level increased in the patient group as a result of stress factors and cellular degeneration due to oxidative damage caused by aphthovirus.

One of the important antioxidants that prevent lipid peroxidation and the accumulation of free radicals is glutathione (GSH) (Mates, 2000). GSH is one of the nonenzymatic antioxidant defense systems. GSH is frequently measured to determine oxidative stress in the blood (Cenesiz, 2020). The level of GSH decreases during oxidative stress (Yurdakul and Saritas, 2013). Studies on foot and mouth disease have reported that GSH levels decreased in the patient groups (Uzlu et al., 2016, Cenesiz 2020). In the current study, we think that the GSH level decreased as a result of pathological changes in tissues

and organs due to cellular damage caused by the increase in oxidants. One of the main reasons for this finding is the increase in free radicals and lipid peroxidation due to foot and mouth disease.

Creatinine is a toxic substance and one of the end products of muscle metabolism. Serum creatinine levels increase as a result of protein catabolism due to infectious conditions, hunger, and high fever. Blood pressure is observed to decrease in cases of fluid loss in the body. Consequently, prerenal azotemia develops due to the decrease in glomerular filtration rate, and renal functions are impaired. Therefore, serum creatinine levels increase (Sezer and Gokce, 2021). In foot and mouth disease, serum creatinine level increases depending on the damage to soft tissues such as the liver, heart, and kidney (Salim et al., 2019). In this study, serum creatinine levels were found to be higher compared to the control group because kidney damage may have been formed in the animals infected with foot and mouth disease. Studies have reported that serum magnesium levels decrease significantly as a result of impaired immune system function in acute viral infections (Yoruk et al., 2014). In this study, it was determined that serum magnesium levels decreased in animals infected with foot and mouth disease. One of the most apparent symptoms of diseases in animals is loss of appetite. In severe disease cases, a decrease in phosphorus level is observed in the body due to anorexia (Akyuz and Aydin, 2022). Another reason for the decrease in phosphorus levels is malabsorption due to enteritis (Sezer and Gokce, 2021, Akyuz et al., 2022b). In this study, it was determined that the serum phosphorus level decreased in the patient group compared to the control group. The possible cause of this is the severe course of the infection and the nutrition deficiency in the animal. In addition, serum phosphorus levels decreased due to malabsorption secondary to enteritis in the patient group infected with foot and mouth disease. Alkaline phosphatase (ALP) is an isoenzyme group located in the outer layer of the cell membrane. One of its most important tasks is to catalyze the hydrolysis of organic phosphate esters in the extracellular space. Alkaline phosphatase levels generally decrease due to nutritional deficiency (Krupaa et al., 2020). In this study, serum ALP enzyme activity was found to be lower in the patient group compared to the control group. We think that the main reason for this may be the lack of magnesium, protein, and phosphorus in the patient group due to nutritional deficiency (Coskun and Sen, 2012). One of the causes of hypoglycemia in severe infectious diseases is the decrease in glycogen due to impaired glucose metabolism in the liver (Sen et al., 2009) along with lack of appetite and hunger (Sezer and Gokce, 2021). In this study, it was determined that the blood glucose level decreased in the patient group compared to the control group. In foot and mouth disease, soft tissue damage develops especially in vital organs such as the liver and heart (Salim et al., 2019). Due to the damage to the liver, glucose metabolism is impaired, and the level of glycogen stores decreases. Furthermore, it was believed that loss of appetite and hunger due to lesions in the mouth and secondary infections in animals infected with foot and mouth disease are among the main causes of hypoglycemia. In severe inflammatory diseases, the regeneration time in soft tissues is prolonged in living organisms due to the impairment of the balance between

anabolic and catabolic activities. One of the most important reasons is the impairment of energy metabolism due to mitochondrial changes (Lepper et al., 2011) and proteolysis resulting from the impairment of transmission in cell membranes (Sezer and Gokce, 2021). Serum creatine kinase enzyme activity increases as a result of myopathy (Sezer and Gokce, 2021, Akyuz and Gokce, 2021). In this study, it was determined that serum creatine kinase enzyme activity was higher in the patient group compared to the control group.

CONCLUSION

Consequently, foot and mouth disease is an important viral infectious disease that has a severe clinical course and causes oxidative stress in cattle. Among the hematological parameters measured in the study, the number of WBCs was determined to have increased. Among the biochemical parameters, a decrease was found in Fe, TIBC, TS, GSH, P, Mg, ALP, and glucose levels while the MDA, Crea, and CK enzyme activities were found to have increased.

DECLARATIONS

Ethics Approval

Kafkas University Local Ethics Committee of Animal Experiments (KAU-HADYEK/2022-032)

Conflict of Interest

There is no conflict of interest.

Consent for Publication

All authors have permission to publish.

Author contribution

Idea, concept and design: MS, TG, OM, EA, KB, GG

Data collection and analysis: MS, TG, OM, EA, KB, GG

Drafting of the manuscript: MS, TG, OM, EA, KB, GG

Critical review: MS, TG, OM, EA, KB, GG

Data Availability

The data that support the findings of this study are available from the corresponding author upon reasonable request

Acknowledgements

Not applicable.

REFERENCES

- Akyuz, E., & Gokce, G. (2021). Neopterin, procalcitonin, clinical biochemistry, and hematology in calves with neonatal sepsis. *Tropical Animal Health Production*, 53, 354. <https://doi.org/10.1007/s11250-021-02779-z>
- Akyuz, E., Makay, M., Kuru, M., & Bayram, P. (2021). The effect of *Tarantula cubensis* extract on gentamicin-induced acute kidney injury in ovariectomized rats. *Kafkas Universitesi Veteriner Fakultesi Dergisi*, 27, 559-566. <https://doi.org/10.9775/kvfd.2021.25390>
- Akyuz, E., & Aydin, U. (2022). Prognostic value of haptoglobin and ceruloplasmin levels determined in cows with adhesive and non-adhesive traumatic reticuloperitonitis. *Kafkas*

Universitesi Veteriner Fakultesi Dergisi, 28, 337-344. <https://doi.org/10.9775/kvfd.2021.27040>

Akyuz, E., Merhan, O., Aydin, U., Sezer, M., Kuru, M., Karakurt, E., Yildiz, U., Bozukluhan, K., Batu, Y.U., Yildiz, A., & Gökce, G. (2022a). Neopterin, procalcitonin, total sialic acid, paraoxonase-1 and selected haematological indices in calves with aspiration pneumonia. *Acta Veterinaria Brno*, 91, 115-124. <https://doi.org/10.2754/avb202291020115>

Akyuz, E., Sezer, M., Kuru, M., & Naseri, A. (2022b). Changes in hematology, some clinical biochemical parameters and mineral levels in neonatal calves with sepsis due to diarrhea. *Van Veterinary Journal*, 33(1), 26-30. <https://doi.org/10.36483/vanvetj.1066050>

Asif, N., Ijaz, A., Rafi, T., Haroon, Z.H., Bashir, S., & Ayyub, M. (2016). Diagnostic accuracy of serum iron and total iron binding capacity (tIBC) in iron deficiency. *State Journal of the College of Physicians and Surgeons Pakistan*, 26(12), 958-961.

Baydar, E., & Dabak, M. (2014). Serum iron as an indicator of acute inflammation in cattle. *International Journal of Dairy Science*, 97, 222-228. <https://doi.org/10.3168/jds.2013-6939>

Beutler, E., Duron, O., & Kelly, B.M. (1963). Improved method for the determination of blood glutathione. *Journal of Clinical Medicine*, 61, 882-888.

Bozukluhan, K., Merhan, O., Kiziltepe, S., Ergin Egritag, H., Akyuz, E., & Gokce H.I. (2021). Determination of haptoglobin, some biochemical and oxidative stress parameters in calves with pneumonia. *Fresenius Environmental Bulletin*, 30, 9485-9489.

Coskun, A., & Sen, I. (2012). Haematological, biochemical and coagulation changes in calves with endotoxemia. *Journal of Agricultural Science and Technology*, 7, 37-41.

Cenesiz, S. (2020). The role of oxidant and antioxidant parameters in the infectious diseases: a systematic literature review. *Kafkas Universitesi Veteriner Fakultesi Dergisi*, 26, 849-858.

Elsayed, M.E., Sharif, M.U., & Stack, A.G. (2016). Transferrin saturation: a body iron biomarker. *Advances in Clinical Chemistry*, 75, 71-97. <https://doi.org/10.1016/bs.acc.2016.03.002>

Gakuya, D.W., Mulei, C.M., & Wekesa, S.B. (2011). Use of ethnoveterinary remedies in the management of foot and mouth disease lesions in a dairy herd. *Trends and Challenges of Traditional Medicine in Africa*, 8, 165-169. <https://doi.org/10.4314/ajtcam.v8i2.63204>

Ganz, T., & Nemeth, E. (2009). Iron sequestration and anemia of inflammation. *Seminars in Hematology*, 46, 387-393. <https://doi.org/10.1053/j.seminhematol.2009.06.001>

Gomme, P.T., McCann, K.B., & Bertolini, J. (2005). Transferrin: structure, function and potential therapeutic actions. *Drug Discovery Today Technologies*, 10, 267-273. [https://doi.org/10.1016/S1359-6446\(04\)03333-1](https://doi.org/10.1016/S1359-6446(04)03333-1)

Gozzelino, R., & Arosio, P. (2016). Iron homeostasis in

health and disease. *International Journal of Molecular Sciences*, 17, 130. <https://doi.org/10.3390/ijms17010130>

Gokce, G., Gokce, H.İ., Güneş, V., Erdoğan, H.M., & Çitil, M. (2004). Alterations in some haematological and biochemical parameters in cattle suffering from foot and mouth disease. *Turkish Journal of Veterinary and Animal Sciences*, 28, 723-727.

Kar, J., Ahad, A., Nath, S.K., Islam, Z., & Sarker, M.S. (2015). Haemato-biochemical aspects of Foot and Mouth disease in cattle in Chittagong, Bangladesh. *International Journal of Molecular Biology*, 3, 62-65. <http://dx.doi.org/10.14737/journal.jimb/2015/3.3.62.65>

Khoshvaghti, A., Askari, A., Nazifi, S., & Ghane, M. (2014). Evaluation of some antioxidant enzymes in cattle infected with foot and mouth virus. *Journal of Faculty of Veterinary Medicine İstanbul University*, 40, 70-75.

Krupaa, R.J., Hariharan, R., Babu, N.A., & Masthan, K.M.K. (2020). Alkaline phosphatase and its clinical importance a review. *European Journal of Molecular & Clinical Medicine*, 7, 1409-1413.

Lepper, C., Partridge, T.A., & Fan, C.M. (2011). An absolute requirement for Pax7-positive satellite cells in acute injury-induced skeletal muscle regeneration. *Development*, 138, 3639-3646. <https://doi.org/10.1242/dev.067595>

Marreiro, D.N., Cruz, K.J.C., Morais, J.B.S., Beserra, J.B., Severo, J.S. & Oliveira, A.R.S. (2017). Zinc and oxidative stress: Current mechanisms. *Antioxidants*, 6, 24. <https://doi.org/10.3390/antiox6020024>

Mates, J.M. (2000). Effects of antioxidant enzymes in the molecular control of reactive oxygen species toxicology. *Toxicology*, 153, 83-104. [https://doi.org/10.1016/s0300-483x\(00\)00306-1](https://doi.org/10.1016/s0300-483x(00)00306-1)

Matsufuji, H., Ochi, H., & Shibamoto, T. (2006). Formation and inhibition of genotoxic malonaldehyde from DNA oxidation controlled with EDTA. *Food and Chemical Toxicology*, 44, 236-241. <https://doi.org/10.1016/j.fct.2005.07.004>

Merhan, O., & Özcan, A. (2010). Peripartum dönemdeki koyunlarda seruloplazmin, haptoglobin, fibrinojen, albümin ve transferrin düzeylerinin araştırılması. *Erciyes Üniversitesi Veteriner Fakültesi Dergisi*, 7, 13-20.

Ozcan, O., Erdal, H., Cakirca, G., & Yonden, Z. (2015). Oxidative stress and its impacts on intracellular lipids, proteins and DNA. *Journal of Clinical and Experimental Investigations*, 6, 331-336.

Salim, S.A.S., Talb, A.O.Q., Saad, A.M.S., & Yousif, A.S. (2019). Clinico-pathological and biochemical aspects of foot and mouth disease in calves. *Advances in Animal and Veterinary Sciences*, 7, 835-843. <http://dx.doi.org/10.17582/journal.aavs/2019/7.10.835.843>

Sezer, M., & Gokce, G. (2021). Studies on sTREM-1, Mr-Pro-Adrenomedullin (Mr-Pro-Adm), clinical biochemistry

and hematology in calves suspected of sepsis. *Kafkas Üniversitesi Sağlık Bilimleri Enstitüsü*, PhD Thesis, Kars.

Sezer, K., & Keskin, M. (2014). Role of the free oxygen radicals on the pathogenesis of the diseases. *Fırat Üniversitesi Sağlık Bilimleri Veteriner Dergisi*, 28, 149-156.

Sen, I., Altunok, V., Ok, M., Coskun, A., & Constable, P.D. (2009). Efficacy of oral rehydration therapy solutions containing sodium bicarbonate or sodium acetate for 109 treatment of calves with naturally acquired diarrhea, moderate dehydration, and strong ion acidosis. *Journal of the American Veterinary Medical Association*, 234, 926-934. <https://doi.org/10.2460/javma.234.7.926>

Talukder, S., Gabai, G., & Celi, P. (2015). The use of digital infrared thermography and measurement of oxidative stress biomarkers as tools to diagnose foot lesions in sheep. *Small Ruminant Research*, 127, 80-85.

Tapiero, H., Gate, L., & Tew, K.D. (2001). Iron: deficiencies and requirements. *Biomedicine and Pharmacotherapy*, 55, 324-332. [https://doi.org/10.1016/s0753-3322\(01\)00067-1](https://doi.org/10.1016/s0753-3322(01)00067-1)

Tsukano, K., Shimamori, T., & Suzuki, K. (2020). Serum iron concentration in cattle with endotoxaemia. *Acta veterinaria Hungarica*, 68, 53-58. <https://doi.org/10.1556/004.2020.00016>

Uzlu, E., Karapehlivan, M., Erdoğan, H.M., Kızıltepe, Ş., Erkilic, E.E., Deveci, H.A., Gökçe, E., Kaya, İ., & Çitil, M. (2016). Serum and saliva sialic acid and oxidative stress parameters changes in bulls with foot and mouth disease. *Kafkas Üniversitesi Veteriner Fakültesi Dergisi*, 22, 321-325.

Wong, C.L., Yong, C.Y., Ong, H.K., Ho, K.L., & Tan, W.S. (2020). Advances in the diagnosis of foot and mouth disease. *Frontiers in Veterinary Science*. 7. <https://doi.org/10.3389/fvets.2020.00477>

Yilmaz, O., & Gokce, G. (2017). Investigations on clinic, haematology, biochemistry, oxidative stress, acute phase proteins in infectious respiratory disease complex (BRDC) in cattle. *Atatürk Üniversitesi Veteriner Bilimler Dergisi*, 12, 34-44

Yoshioka, T., Kawada, K., Shimada, T., & Mori, M. (1979). Lipid peroxidation in maternal and cord blood and protective mechanism against active-oxygen toxicity in the blood. *American Journal of Obstetrics & Gynecology*, 135, 372-376. [https://doi.org/10.1016/0002-9378\(79\)90708-7](https://doi.org/10.1016/0002-9378(79)90708-7)

Yoruk, I.H., Tanritanir, P., Dede, S., Ceylan, E., & Ragbetli, C. (2014). Antioxidant vitamins and microminerals in cows with foot and mouth disease. *Indian Journal of Animal Research*, 48, 593-596.

Yurdakul, G., & Saritas, Z.K. (2013). Evaluation of clinic, radiographic and some biochemical blood serum and synovial fluid parameters of arthritis cases in calves. *Kocatepe Veterinary Journal*, 6, 13-22.

Evaluation of neuroophthalmologic examination in cats and dogs: A retrospective study: 110 cases (2023)

Özlem Şengöz Şirin¹, Muhammed Yusuf Şirin¹, Ayşe Nihan Elvan²

¹Department of Surgery, Faculty of Veterinary Medicine, Burdur Mehmet Akif Ersoy University, Burdur, Türkiye

²Department of Surgery, Institute of Health Sciences, Burdur Mehmet Akif Ersoy University, Burdur, Türkiye

Key Words:

cat
dog
eye
neuro-ophthalmology

Received : 11 November 2023
Revised : 14 February 2024
Accepted : 21 February 2024
Published : 12 June 2024
Article Code : 1389467

Correspondence:

Ö. ŞENGÖZ ŞİRİN
(ozlemsirin@mehmetakif.edu.tr)

ORCID

Ö. ŞENGÖZ ŞİRİN : 0000-0002-2232-6349
MY. ŞİRİN : 0000-0002-7419-5774
AN. ELVAN : 0009-0006-2175-2721

ABSTRACT

This retrospective study includes 20 cats and 90 dogs brought to the Surgical Clinic of Burdur Mehmet Akif Ersoy University Faculty of Veterinary Medicine Animal Hospital with various diseases between January and June 2023. In addition to routine eye examinations, neuro-ophthalmological examinations (nystagmus, strabismus, pupillary light reflex, palpebral reflex, corneal reflex, menace reflex, dazzle reflex) were performed on the patients, and the results of neuro-ophthalmological and routine eye examinations were evaluated retrospectively. Of the cats examined, 55% had pathology on routine ophthalmologic examination and 45% had pathology on neuro-ophthalmologic examination. Pathology was detected in 52.22% of dogs on routine ophthalmologic examination and 22.22% on neuro-ophthalmologic examination. One dog with microphthalmia could not be examined. This study aimed to investigate the prevalence of neuroophthalmological diseases in dogs and cats. This study showed that many neuro-ophthalmological diseases are likely to be overlooked during the examination, and diagnosis may be difficult. Therefore, neuroophthalmological examinations should be added to routine ophthalmological examinations.

INTRODUCTION

Neuro-ophthalmology is a discipline that examines the complex relationship between the eye and the central nervous system. In this field, a comprehensive understanding of the afferent and efferent pathways is crucial for the localization and diagnosis of neuro-ophthalmological disorders. Abnormalities in the afferent or efferent pathways can lead to changes in vision, eye position, tear production, eye function, sensation, and pupil size, shape, or response. These changes manifest as symptoms of neuro-ophthalmological disorders (Bruyette, 2020; Holmberg, 2020).

Neuro-ophthalmic examination combines neurological examination and ophthalmic evaluation to detect eye disorders arising from neurological diseases. Evaluating the visual system from a neurological perspective is fascinating and unique because components like the retina and optic disc can be observed in a normal patient through neurological examination. Therefore, even in cases where clear neuro-ophthalmic abnormalities are absent, the underlying cause of neurological disease can be determined through a comprehensive assessment of the eyes. This is particularly important for inflammatory and infectious central nervous system diseases (Penderis, 2013; Platt and Olby, 2014).

Especially in cats and dogs; nystagmus (rotatoric, vertical, horizontal, positional), strabismus, anisocoria, pupillary light reflex, swinging flashlight test, dazzle reflex, cotton test, threat reflex, palpebral reflex, corneal reflex are used as diagnostic tests and findings in the detection of problems encountered in

neuro-ophthalmological diagnosis.

In the dazzle reflex, when a strong light is shone on the eye, a slight enlargement and shrinkage occurs in both eyes and the reaction tends to be weaker. The afferent branch is the optic nerve, while the efferent branch of this reflex is the facial nerve (Spiess, 2019). The menace response is provided by a threatening gesture to the eye of interest while the other eye is closed. The first afferent component of the threat response is the retina and therefore an intact ocular environment is required for the initial stimulation of the pathway. The response is transmitted from the retina to the visual cortex via the optic nerve (CN II). From the visual cortex there are anterior projections to the motor cortex, then to the facial nucleus, and then to the facial nerve (CN VII) (Mitchell and Oliver, 2021). The palpebral reflex is elicited by touching the skin of the lateral and medial canthus of the eye separately and observing an appropriate response after each touch. Part of this reflex occurs via the ophthalmic and maxillary branches of the V. cranial nerve (trigeminal nerve) for medial and lateral canthus stimulation, respectively. The efferent component of the reflex occurs via the VII. cranial nerve (facial nerve) (Gelatt and Plummer, 2022).

The pupillary light reflex provides optimal visual perception by accurately adjusting the pupil diameter in response to changing ambient illumination (Sun and May, 2014). When light is shone into the eye, pupil constriction occurs in both eyes, even if only one eye is exposed to light. The response in the illuminated eye is a direct response, while the response

in the other eye is indirect or voluntary (Sun and May, 2014). Axons in the optic system, which are not involved in vision, project to the pretectal nuclei at the midbrain level via the lateral ganglion nucleus instead of synapsing. Most axons of the pretectal nuclei cross to synapse on contralateral general visceral efferent (parasympathetic division) neurons of the oculomotor nerve (cranial nerve III) nuclei, which provide parasympathetic innervation to the pupil (Lorenz et al., 2010).

The corneal reflex is elicited by blinking when the corneal surface is touched with a non-damaging object. The afferent arm of this reflex is mediated by cranial nerve V (trigeminal), while the efferent arm is mediated by cranial nerve VII (Gellatt and Plummer, 2022).

For a successful clinical outcome and a satisfied patient, early and accurate diagnosis of ocular disorders is essential. This is based on a comprehensive, regular, and thorough ophthalmic examination. Examining a patient with ocular disease includes obtaining a detailed medical history and conducting a complete examination of the eye and its surrounding structures. Specific diagnostic tests may be used in some cases, guided by the patient's history and examination findings (Aroch et al., 2008).

A step-by-step approach should be adopted to examine all parts of the eye systematically. This reduces the likelihood of overlooking abnormalities and provides a systematic evaluation. However, the consistency of the protocol is essential, and not every diagnostic test is necessary for every patient. The selection of appropriate tests should be based on the patient's history and examination findings (Mitchell, 2011).

Systematic evaluation of neuro-ophthalmic responses and reflexes is an essential part of ophthalmic examination (Mitchell and Oliver, 2021). In this regard, a veterinarian can easily evaluate eight of the twelve cranial nerves in any routine eye examination (Martin et al., 2018).

This study investigated the frequency of neuro-ophthalmic diseases in cats and dogs brought to the Surgical Clinic of Burdur Mehmet Akif Ersoy University Faculty of Veterinary Medicine Animal Hospital between January and June 2023.

MATERIALS and METHODS

The material for this study consisted of a total of 110 patients (90 dogs and 20 cats) brought to the Surgical Clinic of Burdur Mehmet Akif Ersoy University Faculty of Veterinary Medicine Animal Hospital between January and June 2023.

In addition to routine eye examinations, the cats and dogs included in the study underwent neuro-ophthalmological evaluation. During the general eye examination, an examination was performed using a direct ophthalmoscope in a dark environment. Data were recorded at different diopters. After the direct ophthalmoscope examination, intraocular pressure (IOP) was measured, and the IOP values of the patients were recorded. The ICare® TONOVET tonometer device (TV01; Icare Finland Oy, Helsinki, Finland) was used for IOP measurement. Following IOP measurement, Jones and Fluorescein Dye tests were performed, and the results were recorded.

In the neuro-ophthalmological examination conducted on the patients of the study, factors such as pupillary light reflex, palpebral reflex, menace reflex, corneal reflex and dazzle reflex were evaluated. Strabismus and nystagmus were also evaluated in terms of clinical findings. In the pupillary light reflex examination, a bright light source is brought close to the eye and the ipsilateral pupil constricts (direct) and the contralateral pupil is examined for constriction (indirect). With the menace reflex, the closure of the eyelids was examined by making a sudden movement with the hand to both eyes without creating airflow or noise. With the palpebral reflex, it was examined whether the patient could blink normally. For this, the skin on the medial and lateral canthus of the animal's eye was lightly touched and eyelid closure was examined. In the corneal reflex, the cornea was touched with an object that did not damage the corneal surface, and the retraction of the cornea and the closure of the eyelids were examined. In the dazzle reflex examination, the occurrence of glare or squinting in the animal's eye by directing a strong light source to the eye was considered positive.

The data obtained from these examinations were recorded with examination forms and photographs for each animal species and breed.

RESULTS

This study was conducted by examining 20 cats and 90 dogs brought to the Surgical Clinic of Burdur Mehmet Akif Ersoy University Faculty of Veterinary Medicine Animal Hospital with various diseases between January and June 2023 (Figure 1).

Figure 1. Graphical representation of the percentages of cats and dogs examined.

Of the examined dogs, 13.48% were diagnosed with eyelid pathology (8 entropion, 1 eyelid coloboma, 2 lagophthalmos, 1 neoplasm), 25.84% had conjunctival pathology (14 conjunctivitis, 7 epiphora, 2 hyperemia), 4.49% had third eyelid pathology (2 laceration, 1 protrusion, 1 eversion), 12.36% had cornea and sclera pathology (1 corneal edema, 2 corneal pigmentation, 1 corneal cicatrix, 2 corneal degeneration, 2 episcleritis, 3 corneal vascularization), 8.99% had uvea pathology (2 hyphema, 6 uveitis), and 14.61% had retina pathology (2 retinal detachment, 11 retinitis). The examination of one dog with microphthalmia could not be performed.

Of the examined cats, 5% were diagnosed with eyelid pathology (1 entropion), 15% had conjunctival pathology (1 epiphora, 2 conjunctivitis), 10% had third eyelid pathology (2 protrusion), 20% had cornea and sclera pathology (3 corneal edema, 1 corneal vascularization), 15% had uvea pathology (3 uveitis), and 20% had retina pathology (4 retinitis). (Figure 2).

Figure 2. Percentage graphical representation of eye examinations in cats and dogs.

In the neuro-ophthalmological examination performed in addition to routine eye examination, abnormalities were observed in 22.22% of the dogs. Of these abnormalities, it was noted that 66.67% had no pupillary light reflex, 5.56% had no palpebral reflex, 38.89% had no menace reflex, 27.78% had

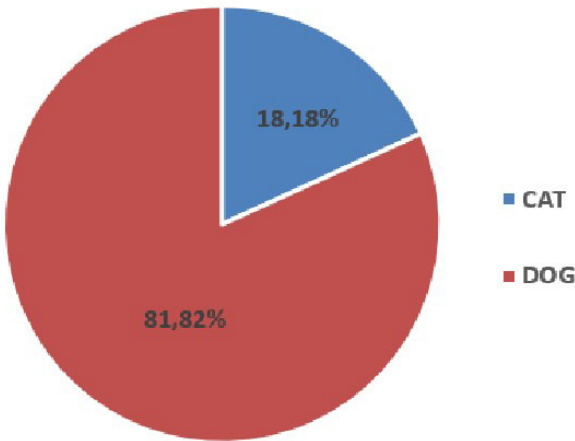


Figure 1. Graphical representation of the number of cats and dogs as a percentage

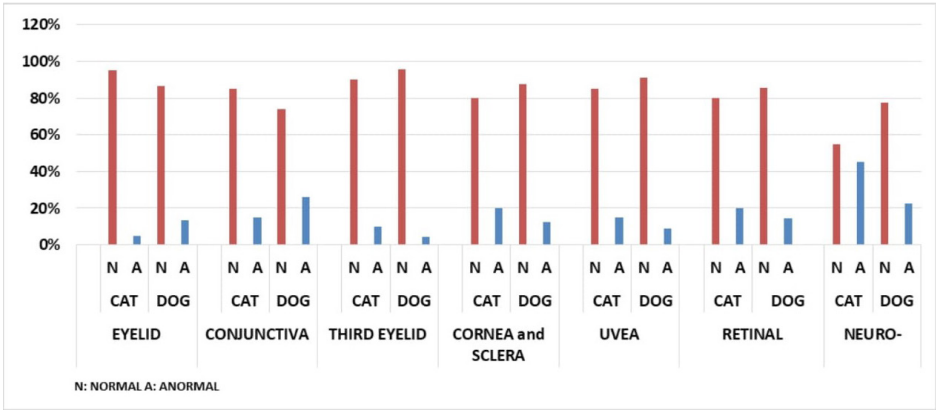


Figure 2. Graphical representation of the percentage of eye examinations performed in cats and dogs

no corneal reflex, and 72.2% had no dazzle reflex. Additionally, 5.56% of the dogs exhibited nystagmus, and 11.11% had strabismus.

In the neuro-ophthalmological examination of cats, abnormalities were observed in 45% of the cases. Among these abnormalities, 81.82% had no pupillary light reflex, 27.27% had

no palpebral reflex, 54.55% had no menace reflex, 54.55% had no corneal reflex, and 81.82% had no dazzle reflex. Additionally, 9.09% of the cats exhibited nystagmus, and 9.09% had strabismus (Figure 3).

Figure 3. Comparison of normal and abnormal values in neuro-ophthalmological examinations of cats and dogs.

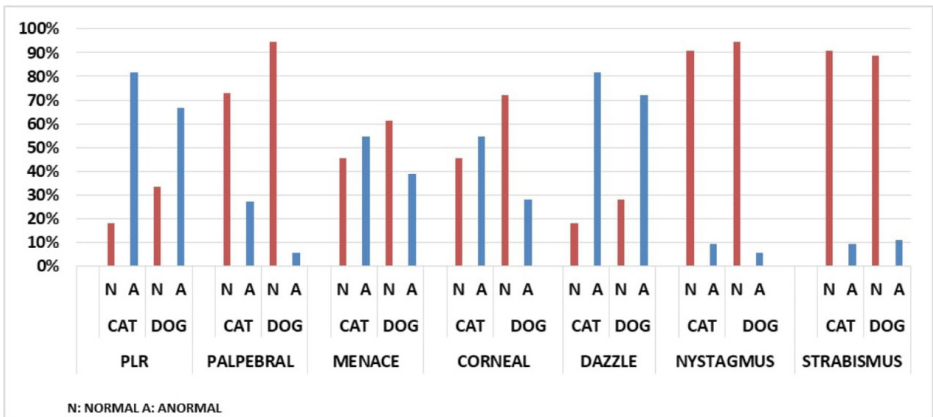


Figure 3. Comparison of normal and abnormal values of neuro-ophthalmological examinations in cats and dogs

In this study, the average IOP in cats was measured as 19.7 mmHg in the right eye and 18.95 mmHg in the left eye. In dogs, the IOP was measured as 23.07 mmHg in the right eye and 22.95 mmHg in the left eye. The IOP values obtained from the patients in this study were within the normal range.

DISCUSSION

Neuro-ophthalmologic problems are encountered more frequently, especially in cases with neurologic diseases. These cases can often go unnoticed during the examination (Brisimi et al., 2017).

Strabismus is an irregular position of the eye that can be positional (occurring when the head is turned upside down) or spontaneous (constantly present) and can be divergent or convergent (Sanders, 2016). Unilateral lesions can lead to dysfunction in the extraocular muscles, affecting the oculomotor (causing divergence), abducens (causing convergence), and trochlear nerves or nuclei. In animals with cleft pupils, trochlear dysfunction becomes evident. Additionally, such lesions can impact the vestibular system, causing positional or vestibular-related strabismus (Polizopoulou and Zavros, 2001; Ofri, 2008b). It's important to differentiate this type of strabismus from conditions such as orbital and muscle diseases, which restrict normal eye movement (Ofri, 2008b).

Positional strabismus, along with nystagmus, has been identified as the most prevalent vestibular symptom of distemper (Amude et al., 2007; Amude et al., 2010). Brisimi et al. (2017) detected nystagmus in 5 dogs with distemper in their study. Strabismus resulting from hydrocephalus typically arises from malformations of the cranial bone around the orbit and mechanical compression, rather than vestibular dysfunction (Polizopoulou and Zavros, 2001; Sanders, 2016). This condition is commonly known as the 'setting sun sign' (Sanders, 2016). Among the dogs diagnosed with idiopathic peripheral vestibular disease, four exhibited ipsilateral strabismus, with three cases being positional and one presenting as spontaneous divergent. In this scenario, spontaneous or vestibular strabismus may arise. It is important to differentiate the latter from a fixed or static strabismus caused by denervation of cranial nerves III, IV, or VI, where the eye remains deviated regardless of head position (Kent et al., 2010). Unilateral strabismus is the most common in this case (Polizopoulou and Zavros, 2001). Positional strabismus, accompanied by nystagmus, observed in cases of ischemic encephalopathy, might be associated with the engagement of the vestibular thalamic area and its afferent connections to the brainstem vestibular nuclei (Garosi et al., 2006; Hillock et al., 2006). Likewise, the secondary impacts of brain tumors, such as edema and hemorrhage compressing the midbrain/brainstem, can lead to cranial nerve deficits and, consequently, result in strabismus (Sanders, 2016). Divergent strabismus is frequently linked with syringomyelia and Chiari-like malformations, though it remains uncertain whether this association stems from oculomotor nerve/muscle paralysis or globe misalignment (Rusbridge, 2013). Intriguingly, a dog diagnosed with presumed post-vaccinal polyradiculoneuritis exhibited a recognized syndrome of bilateral divergent strabismus (Schrauwen and Van Ham, 1995; Gehringa and Eggarsb, 2001; Quiroz Rothe et al., 2005). Its pathogenesis may be linked to

muscle atrophy, similar to what is observed in Guillain-Barré syndrome in humans. In the latter case, symmetrical paralysis of cranial nerve V has been documented to result in complete ophthalmoparesis or limitations in eye movements attributed to cranial nerve V deficits (Gurwood and Drake, 2006). Dogs experiencing neural involvement of the trigeminal nerves in polyradiculoganglioneuritis may present clinical signs such as unilateral atrophy, bilateral paralysis of masticatory muscles, and Horner syndrome (Panciera et al., 2002). In this study, strabismus was found in 11.11% of dogs and 9.09% of cats (1 of these patients had cheri-like malformation, while the other patients had complaints of otitis, fip and trauma).

Nystagmus can manifest as either spontaneous/resting or positional. In cases of vestibular disease, it may present as horizontal, vertical, or rotatory, with the character of nystagmus being either jerky or pendular, determined by the speed of the eye oscillations (Muñana, 2004). "Abnormal nystagmus needs to be differentiated from physiological nystagmus, which arises due to the vestibulo-ocular reflex during head movements (Ofri, 2008b). Lesions impacting the vestibular system, affecting the brainstem nuclei (such as the medial longitudinal fasciculus) or neurons of cranial nerves (CNs III, IV, VI) that innervate extraocular muscles, resulting in the absence of normal vestibular nystagmus (Ofri, 2008b; de Lahunta, 2009). In idiopathic peripheral vestibular syndrome (IPVS), the most common form of nystagmus is horizontal, but sometimes rotatory nystagmus may be observed (Polizopoulou et al., 2006; Ofri, 2008b). The existence of nystagmus, particularly positional, is linked to thalamic/midbrain infarction, indicating the involvement of the vestibular thalamic area and its afferent connections with the brainstem vestibular nuclei (Garosi et al., 2006). In instances of meningiomas, impairment in the diencephalic region, specifically the cerebellum-pontine angle, can result in vestibular symptoms, given that the thalamus functions as a relay station for afferent vestibular inputs to the cortex (Motta et al., 2012). Moreover, meningiomas situated at the cerebellum-pontine angle are frequently linked to clinical symptoms of paradoxical vestibular syndrome (Adamo et al., 2004). In cats, one with vestibular disease of unknown origin and another with head trauma displayed horizontal nystagmus, whereas a cat with FIP encephalitis manifested positional nystagmus. Granulomas linked to FIP can occasionally impede cerebrospinal fluid drainage, leading to secondary hydrocephalus (Sherding, 2006). In this study, nystagmus was observed in 5.56% of dogs and 9.09% of cats.

The normal intraocular pressure in a healthy animal is 15-25 mmHg (Şaroğlu, 2013). In this study, the average intraocular pressure in cats was measured as 19.7 mmHg in the right eye and 18.95 mmHg in the left eye. In dogs, the intraocular pressure was measured as 23.07 mmHg in the right eye and 22.95 mmHg in the left eye.

In a previous study, 35.05% of cats examined ophthalmologically and 35.92% of dogs examined had diagnosed eye pathologies (Şengöz Şirin et al., 2023). In this study, eye pathologies were diagnosed as follows: 13.48% of examined dogs had eyelid pathology (8 entropion, 1 eyelid coloboma, 2 lagophthalmos, 1 neoplasm), 25.84% had conjunctival pathology (14

conjunctivitis, 7 epiphora, 2 hyperemia), 4.49% had third eyelid pathology (2 laceration, 1 protrusion, 1 eversion), 12.36% had cornea and sclera pathology (1 corneal edema, 2 corneal pigmentation, 1 corneal scar, 2 corneal degeneration, 2 episcleritis, 3 corneal vascularization), 8.99% had uveal pathology (2 hyphema, 6 uveitis), and 14.61% had retinal pathology (2 retinal detachment, 11 retinitis). One dog with microphthalmia was unable to undergo an examination.

In the case of examined cats, 5% had eyelid pathology (1 entropion), 15% had conjunctival pathology (1 epiphora, 2 conjunctivitis), 10% had third eyelid pathology (2 protrusion), 20% had cornea and sclera pathology (3 corneal edema, 1 corneal vascularization), 15% had uveal pathology (3 uveitis), and 20% had retinal pathology (4 retinitis).

CONCLUSION

In conclusion, in this study, a total of 110 cat and dog cases presented to our clinic were subjected to neuro-ophthalmological examination in addition to routine eye examinations. These cases were retrospectively evaluated and reported. The neuro-ophthalmological examination is not routinely included among the commonly used eye examinations. However, many central nervous system diseases and systemic diseases manifest as ophthalmic dysfunction. During the examination, the likelihood of overlooking many neuro-ophthalmological diseases and experiencing difficulties in diagnosis is high. Therefore, in addition to a routine eye examination, the neuro-ophthalmological examination should also be added.

DECLARATIONS

Ethics Approval

This study does not present any ethical concerns.

Conflict of Interest

The authors declared that there is no conflict of interest.

Consent for Publication

No applicable.

Author contribution

Idea, concept and design: ÖŞŞ, MYŞ, ANE

Data collection and analysis: ÖŞŞ, MYŞ, ANE

Drafting of the manuscript: ÖŞŞ, MYŞ, ANE

Critical review: ÖŞŞ

Data Availability

The author has provided the required data availability statement, and if applicable, included functional and accurate linksto said data therein.

Acknowledgements

No applicable.

REFERENCES

Adamo, P.F., Forrest, L., Dubielzig, R. (2004). Canine and feline meningiomas: diagnosis, treatment, and prognosis. *Compendium: Continuing Education For Veterinarians*, 26, 951.

Amude, A.M., Alfieri, A.A., Alfieri, A.F. (2007). Clinico-pathological findings in dogs with distemper encephalomyelitis presented without characteristic signs of the disease. *Research in Veterinary Science*, 82, 416–422.

Amude, A.M., Alfieri, A.F., Alfieri, A.A. (2010). Clinical courses and neurological signs of canine distemper virus infection in dogs. *Current research, technology and education topics in applied microbiology and microbial biotechnology*, Sao Paulo, 723-7328.

Aroch, I., Ofri, R., Sutton, G.A. (2008). Ocular manifestations of systemic diseases. In: Maggs, D.J., Miller, P.E., Ofri, R., *Slatter's fundamentals of veterinary ophthalmology* (pp.390-428). Elsevier.

Brisimi, N. M., Liatis, T. K., Komnenou, A., Charalambidou, G., Soubasis, N., Polizopoulou, Z. S. (2017). Neuro-ophthalmological abnormalities in neurological diseases of dogs and cats: a retrospective study of 114 cases (2010-2015). *Journal of the Hellenic Veterinary Medical Society*, 68(3), 433-444. doi: 10.12681/jhvms.15538.

de Lahunta, G. (2009). Chapter 7: Lower Motor Neuron: General Visceral Efferent System. In: *Veterinary neuroanatomy and clinical neurology*, (3rd ed., pp.168-191). ELSEVIER Saunders, St. Louis, Missouri.

Garosi, L., McConnell, J.F., Platt, S.R., Barone, G., Baron, J.C., de Lahunta, A., Schatzberg, S.J. (2006). Clinical and Topographic Magnetic Resonance Characteristics of Suspected Brain Infarction in 40 Dogs, *Journal of Veterinary Internal Medicine*, 20, 11–321.

Gehringa, R., Eggarsb, B. (2001), Suspected post-vaccinal acute polyradiculoneuritis in a puppy, *Journal of the South African Veterinary Association*, 72(2), 96.

Gelatt, K.N., Plummer, C.E. (2022). Chapter 18: Neuro-Ophthalmology. *Essentials of Veterinary Ophthalmology* (4th ed., pp.793-783), USA: Wiley Blackwell.

Gurwood, A.S., Drake, J. (2006) Guillain-Barré syndrome, *Optometry*, 77, 540-546.

Hillock, S.M., Dewey, C.W., Stefanacci, J.D., Fondacaro, J.V. (2006). Vascular encephalopathies in dogs: incidence, risk factors, pathophysiology, and clinical signs, *Compendium on continuing education for the practicing veterinarian*. North American Edition, 28(3), 196-207.

Holmberg, B.J. (2020). Neuroophthalmology. In: Bruyette, D.S. (Ed.). *Clinical Small Animal Internal Medicine* (1st ed., pp. 823-829). John Wiley & Sons.

Kent, M., Platt, S.R., Schatzberg, S.J. (2010). The neurology of balance: Function and dysfunction of the vestibular system in dogs and cats, *The Veterinary Journal*, 185, 278-258.

Lorenz, M.D., Coates, J., Kent, M. (2010). Blindness, Anisocoria and Abnormal Eye Movements. *Handbook of Veterinary Neurology* (5th ed., pp.330-345). USA: Elsevier Health Sciences.

- Martin, C.L., Pickett, J.P., Spiess, B.M. (2018). Neuro-Ophthalmic Disorders. In: Ophthalmic Disease in Veterinary Medicine (pp. 91- 119). CRC Press.
- Mitchell, N., Oliver, J. (2021). The eyelids, nictitans and lacrimal system. In: Feline Ophthalmology The manual (pp. 61-88). Spain: Grupo Asis Biomedica SL.
- Mitchell, N. (2011). Approach to ocular examination in small animals. In Practice, 33(4), 146-154.
- Mitchell, N., Oliver, J. (2021). Chapter 12: Neuro-ophthalmology. Feline Ophthalmology The manual (p.194-208). Spain: Grupo Asis Biomedica SL.
- Motta, L., Mandara, M.T., Skeritt, G.C. (2012) Canine and feline intracranial meningiomas: An update review, The Veterinary Journal, 192, 153-165.
- Muñana, K.R. (2004) Chapter 10: Head tilt and nystagmus. In: Platt, S., Olby, N. (Ed.). BSAVA Manual of Canine and Feline Neurology (3rd ed., pp.155-171). BSAVA.
- Ofri, R. (2008). Chapter 16: Neuro-ophthalmology. In: Maggs, D.J., Miller, P.E., Ofri, R. (Ed.). Slatter's Fundamentals of Veterinary Ophthalmology (4th ed., pp.318-351). ELSEVIER Saunders.
- Panciera, R.J., Ritchey, J.W., Baker, J.E., Digregoriot, M. (2002). Trigeminal and Polyradiculoneuritis in a Dog Presenting with Masticatory Muscle Atrophy and Horner's Syndrome, Vet Pathol, 39, 146-149.
- Penderis, J. (2013). Disorders of eyes and vision. In: Platt SR, Olby NJ. (Eds.), BSAVA Manual of Canine and Feline Neurology (pp. 167-194), BSAVA Library.
- Platt, S.R., Olby, N.J. (2014). BSAVA manual of canine and feline neurology. British Small Animal Veterinary Association (4th ed.), BSAVA Library.
- Polizopoulou, Z., Zavros, N. (2001). Neuro-ophthalmological examination in dog and cat. Journal of the Hellenic Veterinary Medical Society, 52(2), 347-354.
- Polizopoulou, Z.S., Danourdis, A.M., Koutinas, A.F. (2006) The vestibular syndrome in dogs and cats. Journal of the Hellenic Veterinary Medical Society, 57(1), 63-68.
- Quiroz Rothe, E., Ginel, P.J., Pérez, J., Lucena, R., Rivero, J.L.L. (2005). European Journal of General Practice, 15(2), 155-160.
- Rusbridge, C. (2013). Chiari-like malformation and syringomyelia. European Journal of General Practice, 23(3), 70-88.
- Sanders, S.G. (2016). Chapter 11: Disorders of Hearing and Balance. In: Dewey, C.W., da Costa, R.C. (Eds.), Practical Guide to Canine and Feline Neurology (3rd ed., pp.277-297). Wiley Blackwell.
- Şaroğlu, M. (2013). Sistemik Göz Muayenesi. Veteriner Oftalmoloji- Kedi ve Köpek Göz Hastalıkları. İstanbul: Nobel Tıp Kitapevleri.
- Schrauwen, E., Van Ham, L. (1995). Postvaccinal acute polyradiculoneuritis in a young dog. Progress in Veterinary Neurology, 6, 68-70.
- Şengöz Şirin, Ö., Çetin, M. N., Neyse, B. (2023). Evaluation of eye diseases in cats and dogs: a retrospective study: 200 cases. Veterinary Journal of Mehmet Akif Ersoy University, 8(1), 44-49.
- Sherding, R.G. (2006). Feline Infectious Peritonitis (Feline Coronavirus). In: Birchard, S.J., Sherding, R.G. (Eds.). Saunders Manual of Small Animal Practice (3rd ed., pp. 132-143). Elsevier Saunders.
- Spiess, B.M. (2019). Chapter 4: Neuro-Ophthalmic Disorders. Ophthalmic Disease in Veterinary Medicine (2nd ed., pp.91-119), USA: CRC Press.
- Sun, W., May, P.J. (2014). Central pupillary light reflex circuits in the cat: I. The olivary pretectal nucleus. Journal of Comparative Neurology, 522(18), 3960-3977.

Incidence of hoof deformities in honamli herd raised semi-intensively

Harun Çınar¹, Muhammed Yusuf Şirin¹

¹Department of Surgery, Faculty of Veterinary Medicine, Mehmet Akif Ersoy University, Burdur, Türkiye

Key Words:

congenital
economic loss
hoof growth
lameness
pasture

Received : 12 November 2023
Revised : 21 April 2024
Accepted : 22 April 2024
Published : 12 June 2024
Article Code : 1389818

Correspondence:

H. ÇINAR
(hcinar@mehmetakif.edu.tr)

ORCID

H. ÇINAR : 0000-0003-4412-8949
MY. ŞİRİN : 0000-0002-7419-5774

ABSTRACT

Although hoof deformities are frequently encountered in small cattle, this situation is ignored by breeder until the animal shows signs of lameness. Nail deformities, environment, nutrition and individual characteristics of the animal are effective in the occurrence of foot diseases. Overgrowth is the most common cause of lameness. Correctly trimming the nails at regular intervals can prevent lameness. Lack of sufficient movement space in hovels and shelters, dung and urine on the floor of the hovel, inadequate walking and not going out to pasture prevent the nail from being sufficiently worn out and cause the nail to grow excessively and become deformed. Some congenital hoof defects, leg and foot posture disorders and similar structures pave the way for foot diseases in small ruminants. It is very important for the herd that animals with this structure are not used as breeding stock. In intensive breeding, foot diseases and hoof deformations cause significant economic losses. The aim of this study was to investigate the incidence of hoof deformities in semi-intensive Honamli goat herds. In the study, 163 Honamli breed goats were examined for hoof deformities. Hoof deformities were detected in 61 of 163 honamli goats. In the distribution of hoof deformities in Honamli goats; 54 (55,10%) of the goats with hoof deformities had lateral deviation hoof, 2 (2,04%) had corkscrew hoof, 2 (2,04%) had cleft hoof and 2 (2,04%) had beak-like hoof. It was concluded that Honamli goats are more resistant to hoof deformities than other small ruminant species and other goat breeds.

INTRODUCTION

The foot consists of a skin covered with a horn-like layer, soft tissues, and nail parts. The horn-like capsule of the live-stock house is formed by the differentiation of cells in the outer layer of living tissue in the hoof. It acts as a weight-bearing shoe and protects the living parts of the hoof (HAYGEM, 2021).

Nail growth is a physiological process. As a result of excessive keratinization in the horn layer that forms the hoof, a regular increase in the hoof walls and sole occurs. Thus, the hoof grows regularly from the front wall, sole and heel (HAYGEM, 2021; Baran, 1997).

Abnormal hoof formations, including corkscrew deformities and inadequate heels are frequently seen in small ruminants. Overgrown and deformed toenails are common in the ones with untreated foot problems or inadequate nail trimming. Excess selenium in the diet can also cause abnormalities in the growth, moisture content, and condition of the nail wall, causing nails to crack and peel (Kaneps, 1996).

Goats are farm animals that produce meat, milk, hair and mohair by consuming cheap roughage, thus contributing economically to both the breeder and the country's economy (Bingöl and Mevliyaogulları, 2020).

Honamli goat, commonly bred in the panoramic landscape

of the Taurus Mountains encompassing the provinces of Antalya, Burdur, Isparta, and Konya, is more suitable for nomadic breeding systems. Due to significant genetic resources within herds and the nomadic lifestyle of breeders, there hasn't been sufficient scientific research conducted on Honamli goats (Topbaş and Dağ, 2019; Elmaz et al., 2012). Its body is generally black with white or brown spots on the forehead and legs. While males typically have curved horns, females are generally hornless. They have small, thick ears and a large, slender body. The distance between the two horns is 2 cm, indicating a degree of purity. The most characteristic feature is its curved nose. The calving rate is 98.8%. The birth weight of kids ranges between 3.86-4.7 kg. Adult females weigh between 70-75 kg, while males range from 80-85 kg. Lactation milk yield ranges from 135-216 kg (Daskiran et al., 2013).

The type of enterprise in goat breeding is determined by climate, soil and pasture conditions, plant and other animal production types and forms, and social and economic factors. In some countries and regions, there are large herds of thousands of animals in large pastures. In line with the recently changing demands in Turkey, semi-intensive or intensive goat breeding systems have begun to be seen, especially in Western Anatolia, the Aegean and Marmara Regions. The increase in demand for goat milk and cheese, especially in big cities, and the high prices of these products have made more professional goat breeding necessary (Daskiran et al., 2013).

In intensive goat breeding, goats obtained from natural conditions may develop various diseases depending on the growing conditions. Especially shelter and ground structure are the most important factors affecting goat foot health (Bingöl and Mevliyaogulları, 2020). Goats that do not go to pasture for a long time may grow taller. This situation makes the movement of the animal difficult and can cause various posture disorders. Especially the growth of hind hoof nails in goats may cause difficulties in vaccination. Therefore, extended hooves should be trimmed without delay. Nail trimming can be easily done with a sharp knife, nail knife or scissors. During nail cutting, care should be taken not to damage the living nail tissue and to shape the nails to ensure comfortable walking. In unintentional injuries, the injured area should be disinfected with disinfectants or juniper tar should be applied to the bleeding area (HAYGEM, 2021; Daskiran et al., 2013). Factors that predispose to foot diseases are wetness of hovel and courtyard floors, genetic defects, pasture conditions, seasonal changes, insufficient or excessive walking, mineral deficiencies and poorly groomed or incorrect nail cutting. Goats' hoof structures adapt to the characteristics of the pasture they graze on. The possibility of foot disease occurring increases during pasture, shelter environment and nutritional changes. Long rainy and humid seasons soften the nails, and cracks and breaks in the nails increase in extremely dry and hot seasons (HAYGEM, 2021).

All goats that do not go to pasture should have nail care done twice a year, and after the care, the animals should receive a foot bath with 8% zinc oxide (92 liters of water, 8 kg of zinc oxide) (HAYGEM, 2021).

This study aimed to investigate the incidence of hoof abnormalities in the semi-intensively raised Honamli goats.

MATERIALS and METHODS

The study instrument consisted of 163 Honamli goats raised semi-intensively. All goats in the herd were 1-5 years old. Goats are raised in the interior of the Mediterranean region of Turkey (37° 68' N, 30° 31' E) where continental climate weather conditions prevail. Goats were housed in semi-open barns and semi-intensive conditions. Housing conditions for animals consist of a traditional earthen floor. Goats were grazed on natural pasture between 8.00-16.00 hours. Goats were fed twice a day between 7-8 am and 15-16 pm with a diet containing 45% hay and 55% concentrate. Apart from this, fresh water was always available in their environment. It was determined that the goats in the farm did not perform any foot bath or routine foot care.

All goats were held in ventrodorsal position and hoof examinations were performed. Those who had nail deformities during the nail examination were recorded in the nail examination form (Figure 1). Excess horns on the hooves and soles and in the interdigital space were removed with a knife.

NAIL EXAMINATION FORM	
Date: / /	
Patient	Patient Owner
Registration Number:	Name-Surname:
Type/Race:	Phone Number:
Name:	Adres:
Age:m/y	
Gender: Male <input type="checkbox"/> Female <input type="checkbox"/>	
Body Condition Score:	
<input type="radio"/> 1 <input type="radio"/> 2 <input type="radio"/> 3 <input type="radio"/> 4 <input type="radio"/> 5	
Walking Examination:	
<input type="radio"/> Normal <input type="radio"/> Hafif Topallık <input type="radio"/> Topallık Şiddetli <input type="radio"/> Topallık	
Hoof Deformities:	
<input type="radio"/> Gaga Tırnak <input type="radio"/> Aynık Tırnak <input type="radio"/> Tırbüyon Tırnak <input type="radio"/> Laterale Kıvrılma <input type="radio"/> Makas Tırnak	
Descriptions:	

Figure 1. Nail Examination Form

RESULTS

Of all 163 Anatolian goats, hoof disorders were diagnosed in 61. As a result of further examination of the hooves, it was determined that 54 (88.52%) had lateral deviation, 2 (3.27%) had corkscrew hooves, 2 (3.27%) had split hooves, and 2 (3.27%) had beak-like hooves. While hoof deformities were observed in most of the animals, especially in 37.42% of them, a range of specific deformities was also seen within the herd. These included lateral deviation affecting 33.12% of the herd, corkscrew claw affecting 1.22% of the animals, split claw affecting 1.22%, and an additional 1.22% affected by beak-like claws (Table 1).

Table 1. Results

Lesion	Number of Goats	Percentage Among Abnormals	Percentage of All Goats
Lateral Curling	54	88.52%	33.12%
Corkscrew Hoof	2	3.27%	1.22%
Split Hoof	2	3.27%	1.22%
Beak Hoof	2	3.27%	1.22%

DISCUSSION

This study aimed to investigate the incidence of hoof abnormalities in the semi-intensively raised Honamli goats. In a study conducted by Yurdakul (2018), it was determined that a significant rate of hoof deformity was present in 62.54% of lame sheep in the spring period before pasture. Similarly, it was observed that the rate of hoof deformities was 87.75% in the autumn period after pasture. According to Yurdakul (2018), the rate of hoof deformities was found to be 67.74% in both periods (Yurdakul, 2018). In the our study, it was found out that the incidence of hoof deformation in Honamli goats was 37.42% (61/163). It was also determined that although the herd used in the study had not previously been conventionally trimmed, the hoof deformities observed were within typical limits.

According to the study conducted by Aguiar et al. (2011), the prevalence of foot diseases was found to be 19.41% (170/876) in sheep and 17.99% (52/289) in goats. The study found that prevalence ranged from 5.77% to 33.85% across various farms. In our study, the rate of hoof deformities in goats was 37.42% (61/163) (Aguiar et al., 2011). In the study, it was found out that the incidence of hoof deformation in Honamli goats was 37.42% (61/163). It was also determined that although the herd used in the study had not previously been conventionally trimmed, the hoof deformities observed were within typical limits.

In the study of Ajuda et al. (2019), on the relationship between hoof deformation and the incidence of hoof length and lameness in goats, the findings revealed a remarkable prevalence of hoof deformity of 58% (Ajuda et al., 2019). In the our study, it was found out that the incidence of hoof deformation in Honamli goats was 37.42% (61/163). It was also determined that although the herd used in the study had not previously been conventionally trimmed, the hoof deformities observed were within typical limits.

Hill et al. (1997) analyzed random samples of 307 adult goats from four large commercial dairy farms. The study found that 91% (2.6% to 24.4%) of these goats had foot disease (Hill et al., 1997). In the study, it was found out that the incidence of hoof deformation in Honamli goats was 37.42% (61/163). It was also determined that although the herd used in the study had not previously been conventionally trimmed, the hoof deformities observed were within typical limits.

In the study of Prado et al. (2022) 12 non-lactating female Saanen goats were used. Hoof deformity was encountered in 81 of 96 hooves of the goats used in the study and the rate of hoof deformity was found to be 84.37%. After trimming the

hoof with nail clippers, the hoof was trimmed again on a certain date. In this case, the rate of hoof deformity decreased to 42.71% (41/96) (Prado et al., 2022). In this study, it was found out that the incidence of hoof deformation in Honamli goats was 37.42% (61/163). According to the results, it is seen that the incidence of hoof deformity is lower in Honamli goats compared to Saanen goats if the hoof cutting shapes are under the same conditions.

Tutuş and Gençlepe (2021) conducted a study on the incidence of foot diseases in 2000 heads of cattle, 4500 heads of sheep and 500 heads of goats. As a result of this study, the incidence rate of foot diseases and hoof deformities was 8.10% in cattle, 9.71% in sheep and 6% in goats, respectively. In the distribution of foot diseases and hoof deformities in cattle; laminitis 3.70% (6 cases), sole ulcer 5.55% (9 cases), heel rot 8.64% (14 cases), interdigital dermatitis 6.17% (10 cases), digital dermatitis 4.93% (8 cases), white line disease 6.79% (11 cases), nail crack 2.46% (4 cases), pointed nail 25.30% (41 cases), blunt nail 13.58% (22 cases), broad-wide and full nail 8.02% (13 cases), open nail 6.17% (10 cases), corkscrew nail 4.32% (7 cases), scissor-like nail 2.42% (4 cases), beak nail 1.85% (3 cases) and 162 cases in total (Tutuş et al., 2021). In the our study, it was found out that the incidence of hoof deformation in Honamli goats was 37.42% (61/163). In the distribution of hoof deformities in Honamli goats; 54 (88.10%) of the goats with hoof deformities had lateral deviation hoof, 2 (3.27%) had corkscrew hoof, 2 (3.27%) had cleft hoof and 2 (3.27%) had beak-like hoof.

CONCLUSIONS

As a result, the incidence rate of hoof deformities in Honamli goats raised semi-intensively was determined as 37.42%. It was concluded that Honamli goats are more resistant to hoof deformities than other small ruminant species and other goat breeds. In addition, it was aimed to raise awareness of animal breeders about hoof and foot diseases and improvement of

shelters for better animal breeding.

DECLARATIONS

Ethics Approval

This study does not present any ethical concerns.

Conflict of Interest

The authors declared that there is no conflict of interest.

Consent for Publication

No applicable.

Author contribution

Idea, concept and design: HÇ, MYŞ

Data collection and analysis: HÇ, MYŞ

Drafting of the manuscript: HÇ, MYŞ

Critical review: HÇ, MYŞ

Data Availability

The author has provided the required data availability statement, and if applicable, included functional and accurate linksto said data therein.

Acknowledgements

No applicable.

REFERENCES

Aguiar, G., Simões, S. V., Silva, T. R., Assis, A. C., Medeiros, J., Garino Jr, F., & Riet-Correa, F. (2011). Foot rot and other foot diseases of goat and sheep in the semiarid region of northeastern Brazil. *Pesquisa Veterinária Brasileira*, 31, 879-884.

Ajuda, I. D. G. G., Battini, M., Stilwell, G. T. (2019). The role of claw deformation and claw size on goat lameness. *Veterinary and Animal Science*, 8, 100080.

Baran, V. (1997) Sığırlarda tırnak bozuklukları ve bunların neden olduğu taban ulkuslarının sağaltımında antibiyotik ve enzim uygulamaları. *Kafkas Üniversitesi Veteriner Fakültesi Dergisi*, 3; (2): 201-210.

Bingöl, S., Mevliyaoğulları, E. (2020, March) Entansif Süt Keçiciliğinde Tırnak Bakım <https://www.ruminantbesleme.com/wp-content/uploads/2020/03/ke%C3%A7i-t%C4%B1rnak-kesimi-son.pdf>

Daskiran, I, Darcan Koluman, N., Konyalı A., 2013. Keçi Yetiştiriciliği (Goat Breeding). 2013. Tarım ve Köyişleri Bakanlığı. Çiftçi Eğitim Serisi Yayınları. Yayın Dairesi Başkanlığı. Yayın No: 2013/71 (İkinci Baskı). Nisan 2013 - Ankara.

Elmaz, Ö., Saatçı, M., Mamak, N., Dağ, B., Aktaş, A. H., Gök, B. (2012). The determination of some morphological characteristics of Honamlı goat and kids, defined as a new indigenius goat breed of Turkey. *Kafkas Üniversitesi Veteriner Fakültesi Dergisi*, 18; (3): 481-485.

HAYGEM (2021, March 15). Keçi Yetiştiriciliği. <https://www.tarimorman.gov.tr/HAYGEM/Menu/24/Keci-Yetistir>

iciligi

Hill, N. P., Murphy, P. E., Nelson, A. J., Mouttrotou, N., Green, L. E., & Morgan, K. L. (1997). Lameness and foot lesions in adult British dairy goats. *Veterinary Record*, 141(16), 412-416.

Kaneps, A. J. (1996). Orthopedic conditions of small ruminants: llama, sheep, goat, and deer. *Veterinary Clinics of North America: Food Animal Practice*, 12(1), 211-231

Prado, V. C. M., Bassoto Filho, J., Yasuoka, M. M., Ollhoff, R. D., Gallo, S. B., & Birgel Junior, E. H. (2022). Effect of trimming of overgrown and deformed claws in goats on morphometric measurements. *Veterinary Research Communications*, 46(3), 947-954. <https://doi.org/10.1007/s11259-022-09890-y>

Topbaş, H., Birol, D. A. (2019). Some Reproductive Characteristics of Honamlı Goats. *Selcuk Journal of Agriculture and Food Sciences*, 33(3), 223-226. Tutuş, D., & Gençcelep, M. (2021). Van Muradiye İlçesinde Ruminantlarda Görülen Ekstremit ve Ayak Hastalıklarının İnsidansı. *Van Veterinary Journal*, 32(2), 82-90. <https://doi.org/10.36483/vanvetj.957429>

Yurdakul İ (2018). Sivas bölgesi koyunlarında ayak hastalıkları prevalansının araştırılması. *Atatürk Üniversitesi Veteriner Bilimleri Dergisi*, 13(1): 77-83.

Effect of seminal plasma treatment on conception rate in ovsynch treated holstein cows

İlktan Baştan¹, Yunus Çetin²

¹Department of Reproduction and Artificial Insemination, Faculty of Veterinary Medicine, Burdur Mehmet Akif Ersoy University, Burdur, Türkiye

²Department of Obstetrics and Gynaecology, Faculty of Veterinary Medicine, Burdur Mehmet Akif Ersoy University, Burdur, Türkiye

Key Words:

artificial insemination
holstein cows
lactation period
seminal plasma infusion

Received : 30 November 2023
Revised : 17 February 2024
Accepted : 21 February 2024
Published : 12 June 2024
Article Code : 1398223

Correspondence:

İ. BAŞTAN
(ibastan@mehmetakif.edu.tr)

ORCID

İ. BAŞTAN : 0000-0001-8155-1960
Y. ÇETİN : 0000-0002-5402-9429

ABSTRACT

The seminal plasma (SP) plays significant roles in fertilization processes including capacitation, acrosome reaction, and interaction between sperm and the oocyte. In addition, the SP provides an immunomodulatory effect by the cytokines that it contains, in the female reproductive tract. The aim of this study was to investigate the effect of intrauterine seminal plasma infusion on the success of artificial insemination (AI) in Holstein cows. In the study, a total of 60 multiparous Holstein cows were treated with the Ovsynch protocol (10 µg GnRH on day 0, 500 µg PGF2α on day 7, and 10 µg GnRH on day 9), and artificial insemination was performed 16-18 h after the second GnRH. The cows were categorized into four groups based on the number of AI during lactation period; Group-I (Control AI≤2): inseminated once or twice, Grup- II (SP+AI≤2): inseminated once or twice and infused intrauterine SP, Grup-III (Control AI≥3): inseminated thrice or more, Grup-IV (SP+AI≥3): inseminated thrice or more and infused intrauterine SP. SPs were obtained from 5 Holstein bulls. They were mixed and infused into the corpus uterine immediately before AI. Pregnancy diagnosis by ultrasonography was performed on the 32nd, 60th and 95th days after AI. The conception rates were found 53.3%, 60%, 26.6% and 40%, respectively, between the groups at the 32nd and 60th days after AI ($P>0.05$). The pregnancy loss was found only in two cows (25%) of Group I, on the day 95th ($P>0.05$). The days of lactation between the groups were 110 ± 23.2 , 104 ± 28.2 , 238 ± 53 and 221 ± 46.7 , respectively, and were found to statistically significant ($P<0.05$). The results indicate that the application of seminal plasma is promising for pregnancy success in re-inseminated cows. However, it is considered that further studies based on proteomics or gene expression profiles of seminal plasma and uterine tissue in a large cow population are needed to verify this prediction.

INTRODUCTION

Holstein cows exhibit decreased reproductive efficiency, due to extensive breeding for heightened milk production over the years. The physiological stress induced by intensive feeding and high milk production is recognized to exert a negative impact on their fertility. Consequently, there is a surge in the occurrence of culls stemming from subpar reproductive performance and infertility among Holstein cows. (Abdalla et al., 2019; Leroy et al., 2008; Nanas et al., 2023; Wathes et al., 2009).

The liquid part of the ejaculate is known as seminal plasma. It is comprised of epididymal fluid and secretions from various glands in the male reproductive system, including the seminal vesicle, prostate, bulbourethral glands, and ampulla. Seminal plasma primarily consists of a specialized biochemical fluid containing nourishing and protective large molecules as well as trace elements that facilitate the transport of sperm during ejaculation. In fact, the majority of the components of seminal plasma adhere to the surface of the sperm and play a crucial role in fertilization processes such as capacitation, the acrosome reaction, and the interaction between the sperm and the oocyte (Juyena and Stelleta, 2012).

The seminal fluid, which contains cytokines and hormones, aids in maintaining pregnancy in the female reproductive sys-

tem. Furthermore, it supports the function of sperm, their transportation to the fallopian tube, and fertilization. Additionally, inflammation due to seminal fluid in the endometrium leads to the production of embryokines, which play a role in regulating embryonic growth and development. It is moreover indicated to aid in maternal recognition of the embryo through regulation of the maternal immune response (Mateo-Otero et al., 2020; Rizo et al., 2019; Vera et al., 2003).

The main objective of bull stations is to produce as many straws of frozen semen as possible from ejaculates. Therefore, in the process of cryopreservation of bull semen, semen production centers tend to increase the dilution rate of the semen in line with developing cryopreservation techniques. This leads to a decrease in the seminal plasma/sperm ratio (Mokhtassi-Bidgoli et al., 2023). This is supported by the fact that the concentration of conventional bull motile sperm per straw which produced or imported into our country has been reduced from 7 million to 5 million as required by legal instructions in the last five years (Funk, 2006; Haygem, 2023; Vincent et al., 2014). A successful cryopreservation process requires the optimal ratio of spermatozoa, seminal plasma, and semen extender compounds. Research suggests that a certain rate of semen dilution does not impact semen quality and fertilization outcomes, but excessive dilution rates adversely affect semen quality and, consequently, fertilization success (Lone et al.,

2020; Vera-Munoz et al., 2009).

Previous studies have suggested seminal plasma treatment improves the success of insemination or in vitro fertilization in humans and some laboratory animals (Bromfield et al., 2014; Saccone et al., 2019; O’leary et al., 2004). However, studies on this subject in dairy cattle are limited and results are variable (Badrakh et al., 2020; Ninpetch et al., 2022; Odhiambo et al., 2009; Ortiz et al., 2019). The aim of this study was to investigate the effect of seminal plasma treatment on conception rate in multiparous Holstein cows that are reproductively healthy and especially re-inseminated.

MATERIALS and METHODS

Animals and experimental design

Sixty Holstein multiparous cows (n= 60) were used in this study. The animals at the farm were housed under the same conditions. General health and reproductive examinations were performed before and during the study and healthy animals were included in the study. In the research, the cows were categorized into four groups based on the number of artificial insemination (AI) during the lactation period;

- Grup-I (Control AI≤2): Inseminated once or twice,
- Grup- II (SP+AI≤2): Inseminated once or twice and infused intrauterine seminal plasma (SP),
- Grup-III (Control AI≥3): Inseminated thrice or more,

- Grup-IV (SP+AI≥3): Inseminated thrice or more and infused intrauterine seminal plasma (SP).

Seminal plazma ve intrauterin infusion

Seminal plasma samples were obtained from 5 Holstein bulls of a commercial company. For this purpose, semen samples were collected by artificial vagina. Then semen samples were centrifuged at 800 rpm for 15 min and seminal plasma was separated (Ozturk et al., 2021). The separated seminal plasmas were pooled and then filled into 0.25ml straws and stored at -20°C until use. Thawed seminal plasma samples were loaded in an AI gun and infused into the corpus uterine immediately before insemination.

Artificial insemination (AI) and pregnancy diagnosis

Ovysnch [day 0 GnRH (10 µg, buserelin acetate, Receptal, İntervet, Türkiye), day 7 PGF2α (500 µg, cloprostenol, Estrumate, CEVA-DİF, Türkiye), day 9 GnRH]] protocol was used for synchronisation (Agaoglu et al., 2020). Cows were inseminated at a fixed time, 16-18 hours after the second GnRH administration, using frozen-thawed bull semen from the same batch. Pregnancy diagnosis by transrectal ultrasonography (7,5 MHz Linear prob, Hasvet® 838, Hasvet, Türkiye) was performed on the 32nd, 60th and 95th days after AI.

Statistical analysis

All data from the study were subjected to normality tests. Non-parametric values between groups were compared statistically using the Kruskal-Wallis test and the Mann-Whitney

Table 1. Days of lactation, conception rate, and pregnancy loss values in groups.

Group	n	Days of lactation	Conception rate (%)			Pregnancy loss (%)
			d 32	d 60	d 95	
Group I (Control AI≤2)	15	110±23.2 ^A	53.3 (8/15)	53.3 (8/15)	40 (6/15)	25 (2/8)
Group II (SP+AI≤2)	15	104±28.2 ^A	60 (9/15)	60 (9/15)	60 (9/15)	0
Group III (Control AI≥3)	15	238±53 ^B	26.6 (4/15)	26.6 (4/15)	26.6 (4/15)	0
Group IV (SP+AI≥3)	15	221±46.7 ^B	40 (6/15)	40 (6/15)	40 (6/15)	0

Grup-I (Control AI≤2): Inseminated once or twice. Grup- II (SP+AI≤2): Inseminated once or twice and infused intrauterine seminal plasma. Grup-III (Control AI≥3): Inseminated thrice or more. Grup-IV (SP+AI≥3): Inseminated thrice or more and infused intrauterine seminal plasma. A,B Means that different letters within the same column different (P<0.05).

U test. One-way analysis of variance (ANOVA) was used to calculate parametric values following the Tukey test for multiple comparisons. The confidence interval or P value < 0.05 was considered statistically significant. The SPSS (Version 23) package program was utilized for the statistical analysis of the study.

RESULTS

The data obtained in the present study are shown in Table 1. The conception rates were found 53.3%, 60%, 26.6% and 40%, respectively, between the groups at the 32nd and 60th days after AI. Although the highest conception rate was found in Group II (60%), the difference between the groups was not statistically significant ($P > 0.05$). The pregnancy loss was found only in two cows (25%) of Group I, on the day 95th. However, the differences in conception and pregnancy loss rates between groups were not statistically significant, on the day 95th. ($P > 0.05$). The days of lactation between the groups were 110 ± 23.2 , 104 ± 28.2 , 238 ± 53 and 221 ± 46.7 , respectively, and were found to statistically significant ($P < 0.05$).

DISCUSSION

After fertilization, the zygote begins mitotic cell division. By the 8th day after fertilization, it reaches the blastocyst stage. During this period, the embryo is directed to implant in an area of the uterine endometrium where vascularization and nourishing uterine secretions are abundant. Maternal immune tolerance is essential for successful embryo implantation. This immune tolerance is mediated by cytokines, proteins that regulate cellular communication in the immune system. The main cytokines detected in bovine endometrium are insulin-like growth factor 1 (IGF1), epidermal growth factor (EGF), fibroblast growth factor 2 (FGF2), interleukins (IL-4, IL-6, IL-10), and transforming growth factor beta (TGF- β). These cytokines stimulate epithelial, stromal and endometrial cells and are effective in embryo attachment, implantation and placenta processes (Ealy et al., 2021; Hirayama et al., 2015; Sugawara et al., 2010).

The composition of seminal plasma includes many proteins and cytokines of different molecular weights and intracellular or extracellular biological activation. Bovine seminal plasma proteins (BSP-1, BSP-2, BSP-3 and BSP-30), lactoferrin, clusterin, lipocalin-type prostaglandin D synthase, osteopontin, acidic seminal fluid protein (aSF), ubiquitin and 25 kDa protein-beta (P25b) are the major seminal plasma proteins found in bull semen. These proteins also enable sperm transport and contribute to fertilisation stages such as capacitation, acrosome reaction and sperm-oocyte interaction (D'Amours et al., 2017; Kasimanickam et al., 2019; Westfalewicz et al., 2017). Interleukin-1 β (IL-1 β), interleukin-6 (IL-6), transforming growth factor-beta (TGF-beta), tumour necrosis factor-alpha (TNF-alpha), interferon-alpha and interferon-beta cytokines were also isolated from bull seminal plasma. These cytokines act synergistically or antagonistically with cytokines in the female genital tract and induce the expression of these cytokines in the uterine endometrium. The reactions of these immunological agents enable immune modulation by controlling the remodeling of uterine tissue and immune responses to antigens (Ib-

rahim et al., 2019; Mateo-Otero et al., 2020; Vera et al., 2003). Despite differences in seminal plasma composition and female genital anatomy, similar immunomodulatory effects were reported in various mammalian species, including humans, horses, sheep, rats, rabbits and mice. (Gardela et al., 2020; Portus et al., 2005; Schjenken & Robertson 2014). However, although recent literature studies in this field reveal the immune modulation effect of SP in the female reproductive tract, studies indicating its effect on fertilisation success are limited.

There are studies indicating the beneficial effect of SP in insemination and in vitro fertilisation applications in humans on pregnancy outcomes, as well as studies indicating that it has no statistically significant effect on pregnancy rates (Ata et al., 2018; Crawford et al., 2015; Friedler et al., 2013; Saccone et al., 2019). Studies in mice indicate a beneficial effect of seminal plasma on pregnancy rates. Bromfield et al. (2014) reported a significant decrease in vitro and in vivo fertilisation rates with spermatozoa from mice with surgical excision of the seminal vesicle gland. Similar results are also observed in the study conducted by Kawano et al. (2014).

Ortiz et al. (2019) investigated the effect of seminal plasma in first-service artificial insemination with conventional and sex-sorted semen in primiparous and multiparous Holstein cows and found no significant difference in pregnancy outcomes. In the same study, it was stated that the birth weights of calves born from the application of seminal plasma with sex-sorted semen were higher than the control group. Additionally, it suggested that seminal plasma may possess nutritive properties during the embryonic stage. The study in mice suggests that the similar effect of SP is not only limited to the embryonic or foetal period but also has a positive effect on postnatal offspring health (Bromfield et al., 2014). It is thought that the absence of foetal loss in Group-2 compared to Group-1 may be due to this immune modulation effect of SP in addition to many acquired factors. Odhiambo et al. (2009), in a study conducted with approximately two thousand beef and dairy cattle, reported that although SP applications increased pregnancy success numerically, there was no statistical difference between the groups. Badrakh et al. (2020) evaluated the effect of seminal plasma applications on endometrial epidermal growth factor and conception rate in repeat-breeders Holstein cows. According to this study, infusing SP into the vagina led to an increase in EGF levels about threefold more compared to infusing SP into the uterus and also it positively impacted conception rates. In the same study, it was reported that SP did not affect EGF and conception rates in fertile cows (Badrakh et al., 2020). Ninpetch et al. (2022), investigated the effect of seminal plasma on endometrial EGF and expression of leptin receptor (Ob-R). The authors noted that although SP treatment had no effect on OB levels, it normalized EGF levels in about half of the repeat breeder cows, resulting in a successful pregnancy after insemination (Ninpetch et al., 2022). The hypothesis of this study was to investigate the effect of seminal plasma in re-inseminated multiparous cows. Although conception rates were numerically higher in SP groups (Group-2 and Group-4), the difference between the groups was statistically insignificant. As a matter of fact, the scientific data obtained in this research are in parallel with the previous

studies performed.

In dairy cattle, the lactation begins calving and peak of lactation is usually observed during the period of 4-8 weeks postpartum. However, due to the negative energy balance, cows are at higher risk of developing diseases that affect fertility, such as metabolic or mastitis, during this period (Leroy et al., 2008; Nanas et al., 2023; Wathes et al., 2009). In order to reduce the risk of these diseases during the peak of lactation, voluntary waiting periods until the first service are considered a probable solution. In a study of Holstein cows treated with three different voluntary waiting periods (VWP-50 d, VWP-125 d, and VWP-200 d), it was stated that although in the VWP-200 d group became pregnant sooner after the VWP, there was no statistically significant difference in pregnancy rates between groups (Ma et al., 2022). A separate study treatment of two voluntary waiting periods (60d and 88d) reported no significant difference in pregnancy rates between treatment groups (Stangaferro et al., 2018). In the current study, the voluntary waiting period was treatment 90 days. Inseminations were carried out on day 110 ± 23.2 and day 104 ± 28.2 of lactation in groups I and II, respectively. In Groups III and IV, animals were inseminated on day 238 ± 53 and day 221 ± 46.7 of lactation, respectively, due to prior unsuccessful inseminations. In parallel with the mentioned studies, no statistically significant relationship was found between days of lactation and conception rate. The Ovsynch synchronization protocol that designed to synchronize estrus and ovulation is a widely used reproductive management tool in dairy cattle. Pregnancy rates achieved through the Ovsynch protocol in lactating dairy cows range from 32% to 76.92% (Birten et al., 2012; Fricke & Wiltbank, 2022). The pregnancy rates obtained in Group I are consistent with those found in previous studies. It is thought that non-congenital and non-infectious repeat breeding factors are responsible for the low pregnancy rates observed in Group III.

It has been stated that the composition of bull seminal plasma can be influenced by individuality, alimentation, age, frequency of semen collection, and season (Byrne et al., 2012; D'Amours et al., 2017; Kasimanickam et al., 2019; Peddinti et al., 2008). In order to avoid this situation, seminal plasma samples obtained from 5 different bulls were pooled and treatment in this study. Similarly, it is thought that the expression rates of immune agents in uterine tissue may vary depending on the individual, nutrition, number of lactations, and age, which could result in different reactions to the seminal plasma infusion (Agaoglu and Beceriklisoy, 2017; Davoodi et al., 2016; Herath, et al., 2009; Tanikawa et al., 2005). This study was carried out in a particular cattle population with limited data. However, the results obtained indicate that the application of seminal plasma is promising in terms of pregnancy success in re-inseminated or repeated breeder cows.

CONCLUSION

The AI success is important for the sustainability of cattle breeding. For this purpose, alternative treatment protocols with AI have been used for the conception of repeat breeders or infertile cows. It is evident from the obtained pregnancy results that the infusion of allogeneic seminal plasma does

not have any adverse effects on inseminations that were performed with Holstein bull semen. Furthermore, it is thought that the seminal plasma treatment with routine insemination procedures in cases of repeat breeders or infertile cows will enhance the chances of achieving successful pregnancy outcomes. However, it is considered that further studies based on proteomics or gene expression profiles of seminal plasma and uterine tissue in a large cow population are needed to verify this prediction.

DECLARATIONS

Ethics Approval

This study was approved by Burdur Mehmet Akif Ersoy University Animal Experiments Local Ethics Committee at the meeting dated 08.06.2023 with the number of 1132 decisions.

Conflict of Interest

The authors have no conflicts of interest.

Author contribution

Idea, concept and design: İB

Data collection and analysis: İB, YÇ

Drafting of the manuscript: İB, YÇ

Critical review: YÇ

Data Availability

The data used to prepare this manuscript are available from the corresponding author when requested.

Acknowledgments

Not applicable.

REFERENCES

- Abdalla, H., Elghafghuf, A., & Elsohaby, I. (2019). Evaluating sire effects on cow fertility: Timed AI and repeat-breeder dairy cows. *Animal Reproduction Science*, 209, 106147. <https://doi.org/10.1016/j.anireprosci.2019.106147>
- Agaoglu, A. R., Adaoglu, O. K., Aslan, S., Kocamuftuoglu, M., Koker, A., Cetin, Y., Gungor, O., & Saatci, M. (2020). The Effects of Presynch-10 and Ovsynch on Some Endometrial Toll-and Nod-like Receptor Gene Expressions in Repeat Breeder Cows. <https://doi.org/10.9775/kvfd.2019.22428>
- Agaoglu, A.R. & Beceriklisoy, H. B. (2017). Immunology of the Ovary and Uterus in Domestic Animals. *Türkiye Klinikleri, Veterinary Science Obstetrics and Gynecology Special Topics*. 2017;3(1):9-16.
- Ata, B., Abou□Setta, A. M., Seyhan, A., & Buckett, W. (2018). Application of seminal plasma to female genital tract prior to embryo transfer in assisted reproductive technology cycles (IVF, ICSI and frozen embryo transfer). *Cochrane Database of Systematic Reviews*, (2). <https://doi.org/10.1002/14651858.CD011809.pub2>
- Badrakh, D., Yanagawa, Y., Nagano, M., & Katagiri, S. (2020). Effect of seminal plasma infusion into the vagina on the normalization of endometrial epidermal growth factor

concentrations and fertility in repeat breeder dairy cows. *Journal of Reproduction and Development*, 66(2), 149-154. <https://doi.org/10.1262/jrd.2019-148>

Birten, E., Zonturlu, A.K., & Korkmaz, Ö. (2012). Sütçü ineklerde ovsynch protokolünü takiben uygulanan flunixin meglumin'in gebelik oranı üzerine etkisi. *Harran Üniversitesi Veteriner Fakültesi Dergisi*, 1(2), 88-91.

Bromfield, J. J., Schjenken, J. E., Chin, P. Y., Care, A. S., Jasper, M. J., & Robertson, S. A. (2014). Maternal tract factors contribute to paternal seminal fluid impact on metabolic phenotype in offspring. *Proceedings of the National Academy of Sciences*, 111(6), 2200-2205. <https://doi.org/10.1073/pnas.1305609111>

Byrne, K., Leahy, T., McCulloch, R., Colgrave, M. L., & Holland, M. K. (2012). Comprehensive mapping of the bull sperm surface proteome. *Proteomics*, 12(23-24), 3559-3579. <https://doi.org/10.1002/pmic.201200133>

Crawford, G., Ray, A., Gudi, A., Shah, A., & Homburg, R. (2015). The role of seminal plasma for improved outcomes during in vitro fertilization treatment: review of the literature and meta-analysis. *Human Reproduction Update*, 21(2), 275-284. <https://doi.org/10.1093/humupd/dmu052>

D'Amours, O., Frenette, G., Bourassa, S., Calvo, E., Blon-din, P., & Sullivan, R. (2018). Proteomic markers of functional sperm population in bovines: comparison of low-and high-density spermatozoa following cryopreservation. *Journal of Proteome Research*, 17(1), 177-188. <https://doi.org/10.1021/acs.jproteome.7b00493>

Davoodi, S., Cooke, R. F., Fernandes, A. C. D. C., Cappel-lozza, B. I., Vasconcelos, J. L. M., & Cerri, R. L. A. (2016). Expression of estrus modifies the gene expression profile in reproductive tissues on day 19 of gestation in beef cows. *Theriogenology*, 85(4), 645-655. <https://doi.org/10.1016/j.theriogenology.2015.10.002>

Ealy, A. D., Speckhart, S. L., & Wooldridge, L. K. (2021). Cytokines that serve as embryokines in cattle. *Animals*, 11(8), 2313. <https://doi.org/10.3390/ani11082313>

Fricke, P. M., & Wiltbank, M. C. (2022). Symposium review: The implications of spontaneous versus synchronized ovulations on the reproductive performance of lactating dairy cows. *Journal of dairy science*, 105(5), 4679-4689. <https://doi.org/10.3168/jds.2021-21431>

Friedler, S., Ben-Ami, I., Gidoni, Y., Strassburger, D., Kasterstein, E., Maslansky, B., & Raziel, A. (2013). Effect of seminal plasma application to the vaginal vault in in vitro fertilization or intracytoplasmic sperm injection treatment cycles a double-blind, placebo-controlled, randomized study. *Journal of Assisted Reproduction and Genetics*, 30, 907-911. <https://doi.org/10.1007/s10815-013-0033-y>

Funk, D. A. (2006). Major advances in globalization and consolidation of the artificial insemination industry. *Journal of Dairy Science*, 89(4), 1362-1368. [https://doi.org/10.3168/jds.S0022-0302\(06\)72203-2](https://doi.org/10.3168/jds.S0022-0302(06)72203-2)

Gardela, J., Jauregi-Miguel, A., Martinez, C. A., Rodríguez-Martínez, H., López-Béjar, M., & Álvarez-Rodríguez, M. (2020). Semen Modulates Inflammation and Angiogenesis in the Reproductive Tract of Female Rabbits. *Animals*, 10(12), 2207. <https://doi.org/10.3390/ani10122207>

Haygem, (2023). Tarım ve Orman Bakanlığı, Hayvancılık Genel Müdürlüğü. Sperma üretim merkezlerinin çalışma usul ve esasları talimatı. <https://www.tarimorman.gov.tr/HAY-GEM/Link/45/Talimatlar>

Herath, S., Lilly, S. T., Santos, N. R., Gilbert, R. O., Goetze, L., Bryant, C. E., & Sheldon, I. M. (2009). Expression of genes associated with immunity in the endometrium of cattle with disparate postpartum uterine disease and fertility. *Reproductive Biology and Endocrinology*, 7(1), 1-13. <https://doi.org/10.1186/1477-7827-7-55>

Hirayama, H., Koyama, K., Sawai, K., Fujii, T., Naito, A., Fukuda, S., & Kageyama, S. (2015). Localization of TGF- β and TGF- β receptor in bovine term placenta and expression differences between spontaneous and induced parturition. *Placenta*, 36(11), 1239-1245. <https://doi.org/10.1016/j.placenta.2015.09.003>

Ibrahim, L. A., Rizo, J. A., Fontes, P. L., Lamb, G. C., & Bromfield, J. J. (2019). Seminal plasma modulates expression of endometrial inflammatory mediators in the bovine. *Biology of Reproduction*, 100(3), 660-671. <https://doi.org/10.1093/biolre/iroy226>

Juyena, N. S., & Stelletta, C. (2012). Seminal plasma: an essential attribute to spermatozoa. *Journal of Andrology*, 33(4), 536-551. <https://doi.org/10.2164/jandrol.110.012583>

Kasimanickam, R. K., Kasimanickam, V. R., Arangasamy, A., & Kastelic, J. P. (2019). Sperm and seminal plasma proteomics of high-versus low-fertility Holstein bulls. *Theriogenology*, 126, 41-48. <https://doi.org/10.1016/j.theriogenology.2018.11.032>

Kawano, N., Araki, N., Yoshida, K., Hibino, T., Ohnami, N., Makino, M., & Umezawa, A. (2014). Seminal vesicle protein SVS2 is required for sperm survival in the uterus. *Proceedings of the National Academy of Sciences*, 111(11), 4145-4150. <https://doi.org/10.1073/pnas.1320715111>

Leroy, J. L. M. R., Van Soom, A., Opsomer, G., Goovaerts, I. G. F., & Bols, P. E. J. (2008). Reduced fertility in high yielding dairy cows: are the oocyte and embryo in danger? Part II mechanisms linking nutrition and reduced oocyte and embryo quality in high yielding dairy cows. *Reproduction in Domestic Animals*, 43(5), 623-632. <https://doi.org/10.1111/j.1439-0531.2007.00960.x>

Lone, S. A., Mohanty, T. K., Bhakat, M., Paray, A. R., Yadav, H. P., Singh, A., Sinha, R., Baithalu, R. K., Rahim, A., Kumar, R., Kumar, P., & Shah, N. (2020). Modification of French mini-straw plug position for cryopreservation of small doses of bull sperm. *Animal Reproduction Science*, 218, 106485. <https://doi.org/10.1016/j.anireprosci.2020.106485>

Ma, J., Burgers, E. E., Kok, A., Goselink, R. M., Lam, T.

- J., Kemp, B., & van Knegsel, A. T. (2022). Consequences of extending the voluntary waiting period for insemination on reproductive performance in dairy cows. *Animal Reproduction Science*, 244, 107046. <https://doi.org/10.1016/j.anireprosci.2022.107046>
- Mateo-Otero, Y., Sánchez, J. M., Recuero, S., Bagés-Arnal, S., McDonald, M., Kenny, D. A., Yeste, M., Lonergan, P., & Fernandez-Fuertes, B. (2020). Effect of exposure to seminal plasma through natural mating in cattle on conceptus length and gene expression. *Frontiers in Cell and Developmental Biology*, 8, 341. <https://doi.org/10.3389/fcell.2020.00341>.
- Mokhtassi-Bidgoli, A., Sharafi, M., & Benson, J. D. (2023). Optimizing Bull Semen Cryopreservation Media Using Multivariate Statistics Approaches. *Animals*, 13(6), 1077. <https://doi.org/10.3390/ani13061077>
- Nanas, I., Dokou, S., Athanasiou, L. V., Dovolou, E., Chouzouris, T. M., Vasilopoulos, S., ... & Amiridis, G. S. (2023). Feeding Flaxseed and Lupins during the Transition Period in Dairy Cows: Effects on Production Performance, Fertility and Biochemical Blood Indices. *Animals*, 13(12), 1972. <https://doi.org/10.3390/ani13121972>
- Ninpetch, N., Badrakh, D., Kyaw, H. M., Kawano, K., Yanagawa, Y., Nagano, M., & Katagiri, S. (2022). Leptin receptor expression and its change in association with the normalization of EGF profile after seminal plasma treatment in repeat breeder dairy cows. *Journal of Reproduction and Development*, 68(3), 209-215. <https://doi.org/10.1262/jrd.2021-142>
- Odhiambo, J. F., Poole, D. H., Hughes, L., Dejarnette, J. M., Inskeep, E. K., & Dailey, R. A. (2009). Pregnancy outcome in dairy and beef cattle after artificial insemination and treatment with seminal plasma or transforming growth factor beta-1. *Theriogenology*, 72(4), 566-571. <https://doi.org/10.1016/j.theriogenology.2009.04.013>
- O'leary, S., Jasper, M. J., Warnes, G. M., Armstrong, D. T., & Robertson, S. A. (2004). Seminal plasma regulates endometrial cytokine expression, leukocyte recruitment and embryo development in the pig. *Reproduction*, 128(2), 237-247. <https://doi.org/10.1530/rep.1.00160>
- Ortiz, W. G., Rizo, J. A., Carvalheira, L. R., Ahmed, B. M. S., Estrada-Cortes, E., Harstine, B. R., & Hansen, P. J. (2019). Effects of intrauterine infusion of seminal plasma at artificial insemination on fertility of lactating Holstein cows. *Journal of Dairy Science*, 102(7), 6587-6594. <https://doi.org/10.3168/jds.2019-16251>
- Ozturk, C., Güngör, Ş., İnanç, M., & Aksoy, N. H. (2021). Investigation of ram sperm acrosome integrity in relation with seminal plasma homocysteine and nesfatin-1 levels. *Kocatepe Veterinary Journal*, 14(1), 123-128. <https://doi.org/10.30607/kvj.831599>
- Peddinti, D., Nanduri, B., Kaya, A., Feugang, J. M., Burgess, S. C., & Memili, E. (2008). Comprehensive proteomic analysis of bovine spermatozoa of varying fertility rates and identification of biomarkers associated with fertility. *BMC Systems Biology*, 2, 1-13. <https://doi.org/10.1186/1752-0509-2-19>
- Portus, B. J., Reilas, T., & Katila, T. (2005). Effect of seminal plasma on uterine inflammation, contractility and pregnancy rates in mares. *Equine Veterinary Journal*, 37(6), 515-519. <https://doi.org/10.2746/042516405775314844>
- Rizo, J. A., Ibrahim, L. A., Molinari, P. C., Harstine, B. R., Piersanti, R. L., & Bromfield, J. J. (2019). Effect of seminal plasma or transforming growth factor on bovine endometrial cells. *Reproduction*, 158(6), 529-541. <https://doi.org/10.1530/REP-19-0421>
- Saccone, G., Di Spiezio Sardo, A., Ciardulli, A., Caissutti, C., Spinelli, M., Surbek, D., & von Wolff, M. (2019). Effectiveness of seminal plasma in in vitro fertilisation treatment: a systematic review and meta-analysis. *An International Journal of Obstetrics & Gynaecology*, 126(2), 220-225. <https://doi.org/10.1111/1471-0528.15004>
- Schjenken, J. E., & Robertson, S. A. (2014). Seminal fluid and immune adaptation for pregnancy—comparative biology in mammalian species. *Reproduction in Domestic Animals*, 49, 27-36. <https://doi.org/10.1111/rda.12383>
- Stangaferro, M. L., Wijma, R., Masello, M., & Giordano, J. O. (2018). Reproductive performance and herd exit dynamics of lactating dairy cows managed for first service with the Presynch-Ovsynch or Double-Ovsynch protocol and different duration of the voluntary waiting period. *Journal of dairy science*, 101(2), 1673-1686. <https://doi.org/10.3168/jds.2017-13425>
- Sugawara, K., Kizaki, K., Herath, C. B., Hasegawa, Y., & Hashizume, K. (2010). Transforming growth factor beta family expression at the bovine feto-maternal interface. *Reproductive Biology and Endocrinology*, 8, 1-12. <https://doi.org/10.1186/1477-7827-8-120>
- Tanikawa, M., Acosta, T. J., Fukui, T., Murakami, S., Korzekwa, A., Skarzynski, D. J., Park, C. K., & Okuda, K. (2005). Regulation of prostaglandin synthesis by interleukin-1 α in bovine endometrium during the estrous cycle. *Prostaglandins & Other Lipid Mediators*, 78(1-4), 279-290. <https://doi.org/10.1016/j.prostaglandins.2005.09.003>
- Vera, O., Vázquez, L. A., & Muñoz, M. G. (2003). Semen quality and presence of cytokines in seminal fluid of bull ejaculates. *Theriogenology* 60(3), 553-558. [https://doi.org/10.1016/S0093-691X\(03\)00031-1](https://doi.org/10.1016/S0093-691X(03)00031-1)
- Vera-Munoz, O., Amirat-Briand, L., Diaz, T., Vasquez, L., Schmidt, E., Desherces, S., Antaon, M., Bencharif, D., & Tainturier, D. (2009). Effect of semen dilution to low-sperm number per dose on motility and functionality of cryopreserved bovine spermatozoa using low-density lipoproteins (LDL) extender: Comparison to Triladyl® and Bioxcell®. *Theriogenology*, 71(6), 895-900. <https://doi.org/10.1016/j.theriogenology.2008.10.010>
- Vincent P, Underwood SL, Dolbec C, et al (2014). Bovine semen quality control in artificial insemination centers. 1019-1031. In Richard M. Hopper (Ed), *Bovine Reproduction*.

Wathes, D. C., Cheng, Z., Chowdhury, W., Fenwick, M. A., Fitzpatrick, R., Morris, D. G., & Murphy, J. J. (2009). Negative energy balance alters global gene expression and immune responses in the uterus of postpartum dairy cows. *Physiological Genomics*, 39(1), 1-13. <https://doi.org/10.1152/physiol-genomics.00064.2009>

Westfalewicz, B., Dietrich, M. A., Mostek, A., Partyka, A., Bielas, W., Nizański, W., & Ciereszko, A. (2017). Analysis of bull (*Bos taurus*) seminal vesicle fluid proteome in relation to seminal plasma proteome. *Journal of Dairy Science*, 100(3), 2282-2298. <https://doi.org/10.3168/jds.2016-11866>

The effects of exercise on vascular responses in rats with type 1 diabetes

Zihni Can¹, Cengiz Ünsal²

¹Ministry of Agriculture and Forestry Inegöl District Directorate, Bursa, Türkiye

²Department of Physiology, Faculty of Veterinary Medicine, Aydın Adnan Menderes University, Aydın, Türkiye

Key Words:

acetylcholine
aorta
exercise
phenylephrine
rat
type 1 diabetes.

Received : 21 February 2024
Revised : 03 April 2024
Accepted : 16 April 2024
Published : 12 June 2024
Article Code : 1439770

Correspondence:

C. ÜNSAL
(cunsal@adu.edu.tr)

ORCID

Z. CAN : 0009-0000-4066-9006
C. ÜNSAL : 0000-0001-7584-0571

This research was supported by Research Fund the Aydın Adnan Menderes University. Project number: VTF-15021.

ABSTRACT

Diabetes causes dysfunctions and damages in different tissues over time. It has been known that exercise has beneficial effects on the pathologies associated with diabetes. This study was aimed to evaluate the effects of moderate swimming exercise on vascular responses in rats with type 1 diabetes. The groups in the experiment were conducted as diabetes, diabetes exercise, exercise, and control. Streptozotocin (50 mg/kg) was intraperitoneally given to induce type 1 diabetes. The rats in group diabetes exercise and exercise were subjected to a swimming protocol was applied 5 days a week and 1 hour a day for 4 weeks after streptozotocin injection. The initial and final blood glucose levels and weekly body weights were measured. At the end of the study, *in vitro* thoracic aorta responses were recorded. A reduction in body weight of rats with type 1 diabetes was determined from week 1 to week 4 ($p < 0.001$). Blood glucose levels were significantly ($p < 0.001$) higher in both diabetic groups than those of controls and group exercise. The 4-week swimming exercise had no effect on blood glucose levels of diabetic rats. The responses of the thoracic aorta to norepinephrine and sodium nitroprusside were not different between groups. The control rats showed the highest relaxation response of the thoracic aorta to acetylcholine while this response gradually decreased in groups diabetes exercise, exercise, and diabetes. In conclusion, it was observed that 4-week moderate swimming exercise regimen corrected endothelium-dependent relaxation responses in rats with type 1 diabetes.

INTRODUCTION

Diabetes mellitus (DM) is a metabolic disorder with multiple etiologies characterized by disturbances in carbohydrate, fat, and protein metabolism due to the defects in insulin secretion or insulin action or both. Patients with diabetes also have an increased risk of developing cardiovascular, peripheral vascular and cerebrovascular diseases (Alberti and Zimmet, 1998). Hypotheses for the mechanisms of hyperglycemia-induced damage have been included increased flow in the polyol pathway, increased advanced glycation end products (AGEs), activation of protein kinase C isoforms and increased flow in the hexosamine pathway (Brownlee, 2001). The causes of vascular dysfunction leading to defective angiogenesis in diabetes are complex. Some of these factors include increased reactive oxygen species and AGEs, decreased growth factors and cytokines, and altered cellular immune responses. Endothelial dysfunction is primarily caused by a reduction in nitric oxide bioavailability and may be caused by or contribute to various disease processes, such as in diabetes mellitus, hypercholesterolemia and hypertension (Kolluru et al., 2012).

The endothelium is essential for maintaining vascular wall integrity and locally regulating vascular tone, structure, and hemostasis. Regular exercise can improve endothelial function through several mechanisms. For example, it increases blood

flow and laminar shear stress, resulting in increased nitric oxide production and bioavailability (Di Francescomarino et al., 2009).

Aerobic exercise also increases mitochondrial density, insulin sensitivity, oxidative enzymes, compliance and reactivity of the blood vessels, pulmonary function, and cardiac output (Garber et al., 2011). Moderate and high levels of aerobic activity lead to significant reductions in cardiovascular and overall mortality risks in both type 1 and type 2 diabetes (Ratamess et al., 2009). In type 1 diabetes, aerobic training increases cardio-respiratory performance, reduces insulin resistance, and improves lipid levels and endothelial function (Chimen et al., 2012). The aim of this study was to investigate the effects of moderate swimming exercise for 4 weeks on vascular response in male rats with type I diabetes mellitus.

MATERIAL and METHODS

Animals and experimental design

Thirty-six adults male Wistar albino rats with an average weight of 350 g were used in the study. The rats were housed in a room under a 12/12 light/dark cycle, at 22 ± 2 °C, and 50 to 70% of humidity with ad libitum access to food and water. The rats were divided into four groups: diabetes ($n=10$), diabetes and exercise ($n=10$), exercise ($n=8$) and sedentary

control (n=8). For induction of type 1 diabetes, a single dose (50 mg/kg) of streptozotocin (2-Deoxy-2-(3-methyl-3-nitrosoureido D-glucopyranose - S0130 1G, Sigma Aldrich®) was administered intraperitoneally. For this purpose, STZ was weighed into Eppendorf tubes (50 mg each), wrapped with aluminum foil, and stored at -20 °C. Freshly prepared 0.1 M sodium citrate buffer (pH: 4.5) was added 1 ml to the tubes, STZ-dissolved and immediately administered to the animals. Seventy-two hours after streptozotocin injection, the rats with 250 mg/dl blood glucose levels or higher were considered diabetic and included in the experiment. An additional blood glucose measurement was done at the end of the experiment. A glucometer and test strips (Bayer Contour Plus®, Germany) were used to measure blood glucose levels from tail vein. Rats were weighed at the beginning of the study and weekly thereafter.

Swimming protocol

Eight days after diabetes induction, a swimming protocol was applied 5 days a week and 1 hour a day for 4 weeks. This intensity of exercise protocol is considered as moderate exercise in rats (Kregel, 2006). Rats were individually swum in plastic containers with a 70 cm of diameter and a 90 cm of height in temperature controlled ($31 \pm 1^\circ\text{C}$) water with a 50 cm of depth (Ünsal et al., 2017).

Preparation of aorta rings

Four weeks after swimming exercise, rats were anesthetized with a combination of ketamine and xylazine (50 mg/kg ketamine-10 mg/kg xylazine Alfamine®, Alfazyne® EGE-VET, Turkey, respectively) and placed supine position on a thermal pad. After skin incision, upper midline median thoracotomy was done. The surrounding organs were then carefully dissected, and the thoracic aortas were separated from the connecting tissues and placed in Krebs bicarbonate solution. Krebs bicarbonate solution was prepared (mM/l) at pH 7.4 (NaCl: 128; KCl: 4.5; CaCl_2 : 2.5; MgSO_4 : 118; KH_2PO_4 : 1.18; NaHCO_3 : 125; D-glucose: 5.55). Vascular rings were made and kept in Krebs bicarbonate solution at $+4^\circ\text{C}$ until use. The vascular rings were connected to the isometric transducer in the chamber of the organ bath and washed every 15 minutes with the Krebs bicarbonate solution in order to allow the tissues to adapt to the environment. The vessels were pre-tensioned (1 g) and left for 1 h. After each experimental protocol, the vessels were given a 30-minute rest period, and the washing process was repeated every 15 minutes (Keegan et al., 1995; Turgut et al., 2008).

For assessment of vascular integrity, phenylephrine (10^{-5} mM) was added into the bath and vascular contraction was recorded. Endothelial integrity in the vessel reaching submaximal contraction was evaluated by measuring the relaxation response to acetylcholine (10^{-5} mM). Additionally, at the beginning of the experiment, KCl (80 mM) was added into the organ bath to assess vascular smooth muscle contractility and the response to phenylephrine. Phenylephrine was applied cumulatively at the concentrations ranging from 10^{-9} - 10^{-4} mM. Endothelium-dependent relaxation responses were evaluated by the cumulative application of acetylcholine (10^{-9} - 10^{-4} mM)

in vessels that were pre-contracted with 10^{-5} mM phenylephrine. Smooth muscle-dependent relaxation responses were evaluated by the cumulative application of sodium nitroprusside at the concentrations ranging from 10^{-9} - 10^{-4} mM in vessels pre-contracted with 10^{-5} mM phenylephrine (Turgut et al., 2008).

Statistical analyses

The data was analyzed using the SPSS 19.0 package program. The arithmetic mean (\bar{x}) and standard error of the mean ($\text{S}\bar{x}$) were determined for each variable. Normal distribution was assessed by Shapiro-Wilk test and homogeneity of variance by Levene's test. Repeated measures analysis of variance was performed for body weight, blood glucose levels, and aortic responses, except for the KCl responses, for which a one-way analysis of variance was performed. Post-hoc Bonferroni and Duncan tests were performed.

RESULTS

Blood glucose levels in the diabetic groups continued to increase significantly ($p < 0.001$) compared to the beginning of the experiment. Although exercise tended to lower blood glucose levels in rats with diabetes, the effect did not reach to the statistically significant level (Figure 1).

At the beginning of the experiment, the body weights were not different among the groups. Induction of diabetes caused a time-dependent reduction in mean body weights of groups diabetes exercise and diabetes over four weeks when compared to the controls and exercise group ($p < 0.001$). The 4-week swimming exercise did not prevent rats from body weight loss caused by diabetes (Figure 2).

In all groups, contraction responses of the aorta rings were obtained in response to KCl (80 mM) which the differences between groups were not statistically significant ($p = 0.918$, Figure 3).

Phenylephrine responses for each concentration were obtained by proportioning the contractile responses to the responses that were obtained with KCl. Therefore, the results were given as % contraction of KCl (Figure 4). The contractile responses of the thoracic aorta to the phenylephrine increased in a dose-dependent manner for each group. However, the changes were not statistically significant ($p = 0.802$).

Sodium nitroprusside responses were calculated from the ratio of the obtained submaximal responses to phenylephrine and given as % relaxation (Figure 5). The relaxation responses increased in a dose-dependent manner. The highest relaxation responses were obtained in the control and exercise groups. However, the differences between groups were not statistically significant ($p = 0.452$).

Acetylcholine responses were obtained from the ratio of the results for each concentration to the submaximal phenylephrine response and given as % relaxation (Figure 6).

The relaxation responses to acetylcholine increased in a dose-dependent manner. Vessels from the rats with diabetes had the least relaxation responses which was found to be sig-

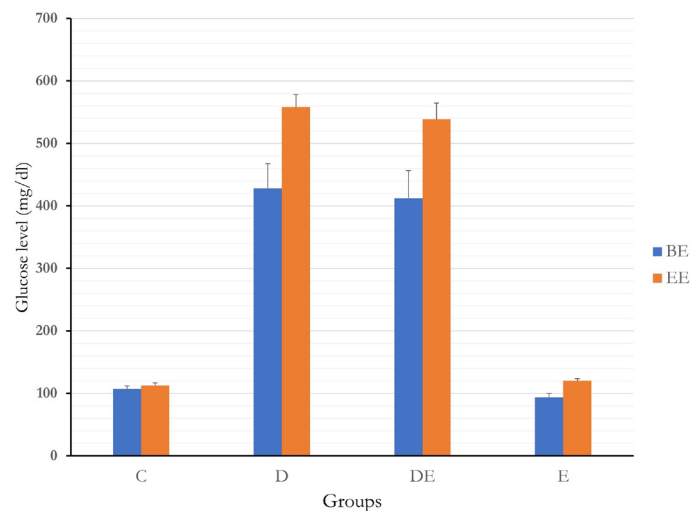
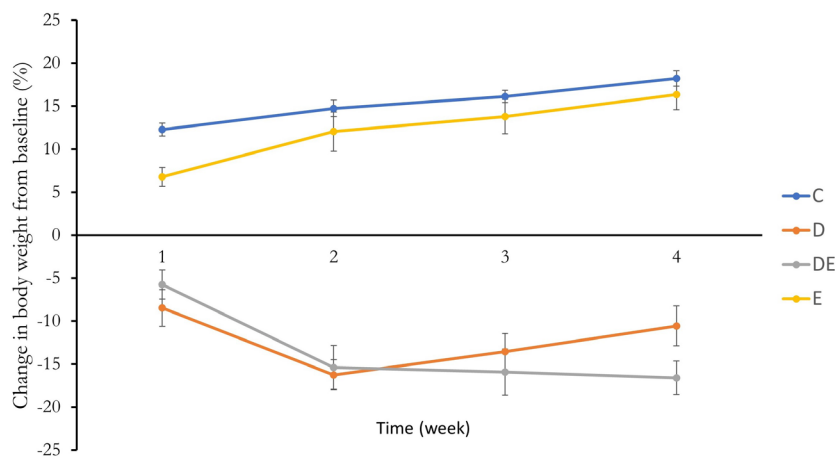


Figure 1. Blood glucose levels in rats (mg/dl).
D: Diabetes, DE: Diabetes exercise, E: Exercise, C: Control.



Groups	C	D	DE	E
0	343,17 ± 13,31	329,14 ± 16,62	343,86 ± 13,31	373,13 ± 11,61
1	385,00 ± 12,41	301,43 ± 17,14	323,86 ± 12,41	398,13 ± 11,95
2	393,67 ± 9,97	275,57 ± 14,74	290,00 ± 9,97	416,38 ± 7,03
3	398,67 ± 13,68	284,43 ± 15,45	289,14 ± 13,68	423,13 ± 7,84
4	405,33 ± 14,15	294,00 ± 15,15	287,29 ± 14,15	432,88 ± 9,01

Figure 2. Body weight changes and change in body weight from baseline (%).
D: Diabetes, DE: Diabetes exercise, E: Exercise, C: Control.

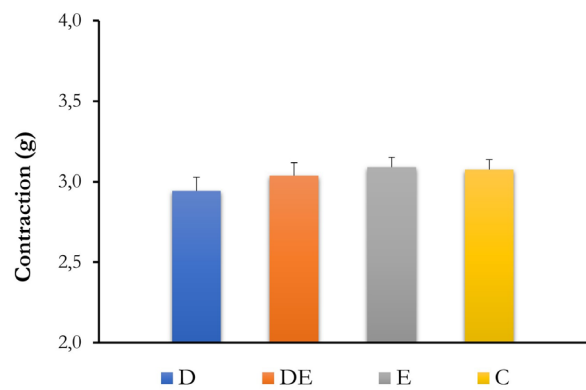


Figure 3. Potassium chloride responses (g).
D: Diabetes, DE: Diabetes exercise, E: Exercise, C: Control.

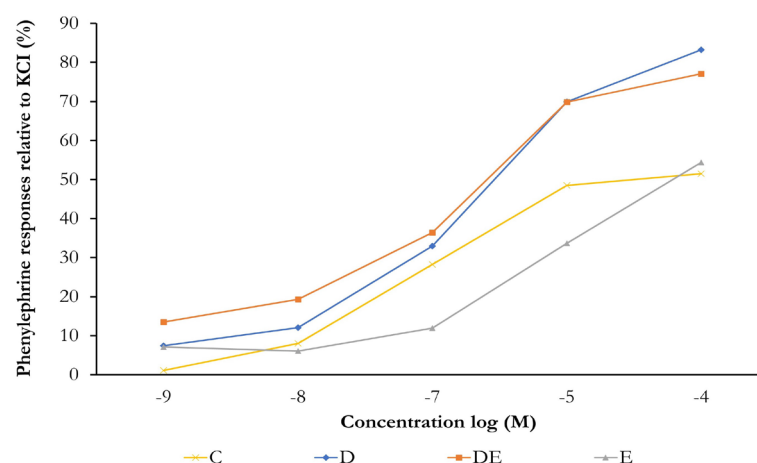


Figure 4. Phenylephrine responses.
D: Diabetes, DE: Diabetes exercise, E: Exercise, C: Control

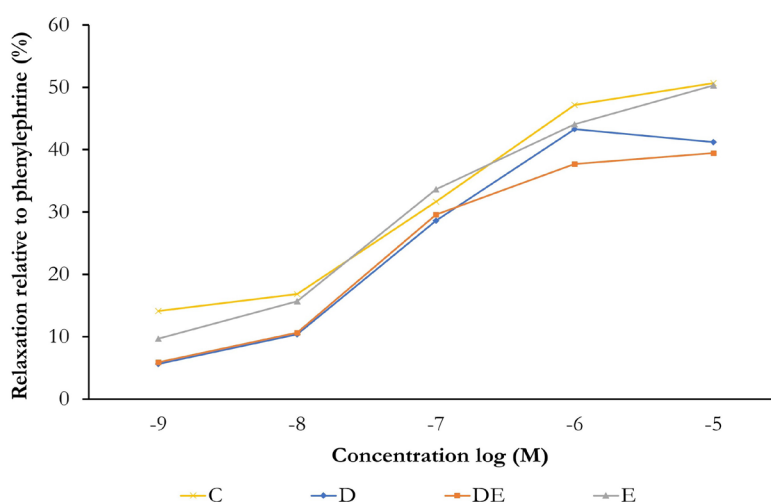


Figure 5. Sodium nitroprusside responses.
D: Diabetes, DE: Diabetes exercise, E: Exercise, C: Control.
The difference between the groups was not statistically different ($p=0.452$).

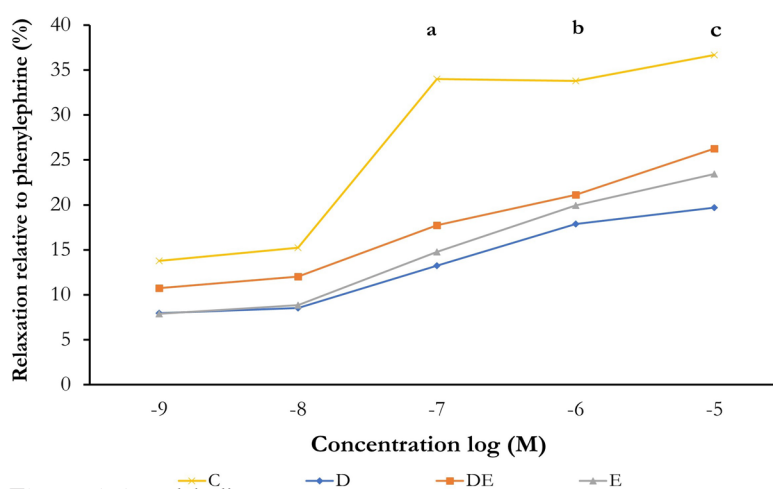


Figure 6. Acetylcholine responses.
D: Diabetes, DE: Diabetes exercise, E: Exercise, C: Control.
a: Diabetes, exercise and diabetes exercise groups were significantly different from the control group ($p=0.037$, $p=0.006$, $p=0.043$, respectively).
b: Diabetes group is significant with the control group ($p=0.011$)
c: Diabetes group is significantly different from diabetes exercise, exercise, and control groups ($p=0.007$, $p=0.007$, $p=0.001$ respectively).

nificant compared to the controls at the concentrations of 10^{-7} , 10^{-6} and 10^{-5} mM ($p=0.001$, $p=0.037$, $p=0.011$, respectively). The responses from the diabetes exercise group were found to be significant compared to the controls at 10^{-7} mM concentration of acetylcholine ($p=0.043$) and this difference disappeared in all other concentrations. The relaxation responses of the exercise group to acetylcholine were weaker than the control group and this difference was significant at 10^{-5} mM concentration of acetylcholine ($p=0.037$). The diabetes exercise group showed a stronger relaxation than the diabetic group and the difference was statistically confirmed for 10^{-5} mM concentration ($p=0.007$).

DISCUSSION

Previous studies showed that exercise did not cause changes in blood glucose levels of rats with type 1 diabetes (Mona and Allam, 2018; Nakos et al., 2018) which is consistent with this study. The type of the physical activity is considered important in terms of glycemic control through exercise. It has been reported that individuals with type 1 diabetes may experience higher glycemic variability during aerobic exercise as compared to the resistance exercise (Yardley et al., 2013). On the other hand, it is also emphasized that aerobic exercise is an appropriate method for chronic glycemic control specifically in humans, while resistance exercise does not have a significant effect on chronic glycemic control (Tonoli et al., 2012).

Compared to the controls, rats with type 1 diabetes lost 23-31% of body weight, while the diabetic exercise group lost 16-29%. The rats with diabetes showed a rapid weight loss and clinical symptoms of polydipsia, polyphagia, and polyuria, although data on these symptoms were not collected in this study. Similar to this study, Nakos et al (2018) observed a weight loss and symptoms of polydipsia and polyphagia in diabetic animals despite the eight-week exercise protocol provided only a partial improvement in body weights, suggesting that exercise alone is insufficient to reverse the effects of diabetes on body weight. However, significant improvements in insulin resistance were determined in exercising rats with type 1 diabetes (Hall et al., 2013) likely due to beneficial effects of long-term aerobic exercise on β -cell proliferation (Kiralý et al., 2007) and oxidative capacity (Torgan et al., 1993). Since insulin levels were not measured in this study, which is a limitation, it is hard to interpret the relationship between body weight change and insulin action.

Although diabetes caused a slight reduction, KCl-induced contraction of the thoracic aorta was not significant between groups. Consistent with this finding, Taylor et al. (1994) noted that KCl-induced contraction responses of mesenteric arteries remained unchanged in diabetic rats, but more recent evidence suggests that contraction responses to KCl increase under hyperglycemic conditions in vitro. Donmez et al. (2014) suggested that this increase may be due to elevated oxidative stress under hyperglycemic conditions. KCl-induced contraction is primarily mediated through voltage-gated calcium channels (Akata, 2007). In contrast to the studies mentioned above, there are also studies showing that KCl responses are reduced in diabetic rats (Fulton et al., 1991; Carmines et al., 1996) which may be due to a decreased density of voltage-gat-

ed L-type Ca^{+2} channels (Wang et al., 2000).

In this study, although not statistically significant, phenylephrine responses fluctuated among groups as evidenced by the fact that an increase in rats with diabetes and a reduction in rats that were subjected to swimming exercise when compared to the controls. Overall, studies have shown that the response to phenylephrine can be unchanged (Fulton et al., 1991; Taylor et al., 1994; Kobayashi and Kamata, 1999), decreased (Oyama et al., 1986), or increased (Karasu and Altan, 1993) in diabetic states.

Sodium nitroprusside acts as an endothelium-independent relaxant, exerting its effect through direct action on vascular smooth muscle (Bonaventura et al., 2008). Previous studies showed that diabetes does not affect SNP-mediated relaxation responses (Oyama et al., 1986; Taylor et al., 1992) which is consistent with this study.

Studies have shown that vasorelaxation, induced by acetylcholine, is dependent on an intact endothelium which is mediated by endothelium-derived relaxing factors such as nitric oxide, prostanooids, and endothelium-derived hyperpolarizing factor (Leung et al., 2006). In this study, endothelium-dependent relaxation, caused by acetylcholine was impaired in the rats with type 1 diabetes. Importantly, the diabetic rats that were subjected to the swimming exercise showed an improved relaxation compared to the rats with diabetes per se and this difference was statistically confirmed at the concentration of 10^{-5} mM acetylcholine.

In rats with type 1 (Oyama et al., 1986; Dai et al., 1993; Taylor et al., 1994; Kobayashi and Kamata, 1999) and type 2 (Oyama et al., 1986) diabetes, endothelium-derived hyperpolarizing factor mediated vasodilation, the total oxidant capacity (Ünsal and Ünsal, 2016) and the production of free radicals and prostaglandin endoperoxidases is altered which may cause an impairment of nitric oxide-mediated endothelium-dependent relaxation (Dai et al., 1993). Although oxidative stress increases in the early stages of diabetes, the endothelial function is preserved. Nitrosothiol serves as an additional source of nitric oxide in this process, ensuring the continuity of endothelium-dependent relaxation (Leo et al., 2010; Joshi and Woodman, 2012). However, this compensatory mechanism may be impaired in the long term and endothelium-dependent relaxation may be damaged (Leo et al., 2010). Exercise seems like partially correct the impaired acetylcholine response in diabetic conditions. It has been shown that endurance exercise in rats with type 2 diabetes has beneficial effects on hyperglycemia and insulin resistance. It also prevents the impairment of endothelium-derived hyperpolarizing factor and endothelial derived relaxation factor (Minami et al., 2002) which suggests that exercise is thought to increase nitric oxide bioavailability and improve endothelial function (Di Francescomarino et al., 2009).

In conclusion, this study shows that type 1 diabetes negatively affects vascular properties of the thoracic aorta in rats. Exercise may have beneficial effects on the impaired processes. Longer duration of exercise could be more effective in ameliorating high blood glucose levels and endothelial dysfunction.

DECLARATIONS

Ethics Approval

The study was approved by the Aydın Adnan Menderes University Animal Experiments Local Ethics Committee (approval number: 64583101/2014/142).

Conflict of Interest

The authors state no conflict of interest.

Consent for Publication

Not applicable.

Author contribution

Idea, concept, and design: CU

Data collection and analysis: ZC, CU

Drafting of the manuscript: ZC, CU

Critical review: CU

Acknowledgements

This study was presented as an oral presentation at the 42nd National Physiology Congress of Turkish Physiological Sciences Association (Düzce University Congress Center 05-08 September 2016). The abstract of the presentation is published in the Congress Proceedings and ACTA Physiologica Volume 215, Issue S704. In addition, the serum samples obtained from the study were analyzed and presented (Oral Presentation) with the title "The Effect of Swimming Exercise on Lipid Profile and Oxidant-Antioxidant Status in Type I Diabetic Rats" in 10th The 10th International Conference in Physical Education, Sports and Physical Therapy (18-20 November 2016 Firat University, Faculty of Sport Sciences, Elazığ). This chapter was published in "F.Ü. Sağ. Bil. Tıp Derg. 2016; 30 (3): 119-123" as full text.

REFERENCES

- Akata, T. (2007). General anesthetics and vascular smooth muscle: direct actions of general anesthetics on cellular mechanisms regulating vascular tone. *Anesthesiology*, 106(2), 365-391. <https://doi.org/10.1097/00000542-200702000-00026>
- Alberti, K. G., & Zimmet, P. Z. (1998). Definition, diagnosis and classification of diabetes mellitus and its complications. Part 1: diagnosis and classification of diabetes mellitus provisional report of a WHO consultation. *Diabetic Medicine*, 15(7), 539-553. [https://doi.org/10.1002/\(SICI\)1096-9136\(199807\)15:7<539::AID-DIA668>3.0.CO;2-S](https://doi.org/10.1002/(SICI)1096-9136(199807)15:7<539::AID-DIA668>3.0.CO;2-S)
- Bonaventura, D., Lunardi, C. N., Rodrigues, G. J., Neto, M. A., & Bendhack, L. M. (2008). A novel mechanism of vascular relaxation induced by sodium nitroprusside in the isolated rat aorta. *Nitric Oxide*, 18(4), 287-295. <https://doi.org/10.1016/j.niox.2008.02.004>
- Brownlee, M. (2001). Biochemistry and molecular cell biology of diabetic complications. *Nature*, 414(6865), 813-820. <https://doi.org/10.1038/414813a>
- Carmines, P. K., Ohishi, K., & Ikenaga, H. (1996). Functional impairment of renal afferent arteriolar voltage-gated calcium channels in rats with diabetes mellitus. *Journal of Clinical Investigation*, 98(11), 2564-2571. <https://doi.org/10.1172/JCI119075>
- Chimen, M., Kennedy, A., Nirantharakumar, K., Pang, T. T., Andrews, R., & Narendran, P. (2012). What are the health benefits of physical activity in type 1 diabetes mellitus? A literature review. *Diabetologia*, 55(3), 542-551. <https://doi.org/10.1007/s00125-011-2403-2>
- Dai, F. X., Diederich, A., Skopec, J., & Diederich, D. (1993). Diabetes-induced endothelial dysfunction in streptozotocin-treated rats: role of prostaglandin endoperoxides and free radicals. *Journal of the American Society of Nephrology*, 4(6), 1327-1336. <http://www.ncbi.nlm.nih.gov/pubmed/8130359>
- Di Francescomarino, S., Sciartilli, A., Di Valerio, V., Di Baldassarre, A., & Gallina, S. (2009). The effect of physical exercise on endothelial function. *Sports Medicine*, 39(10), 797-812. <https://doi.org/10.2165/11317750-000000000-00000>
- Donmez, S., Gokalp, O., Dogan, M., Vural, H., & Yigit, B. (2014). Effects of short-term hyperglycemia on the vasoconstriction of the aorta. *Turkish Journal of Medicine and Science*, 44(6), 941-945. <http://www.ncbi.nlm.nih.gov/pubmed/25552145>
- Fulton, D. J., Hodgson, W. C., Sikorski, B. W., & King, R. G. (1991). Attenuated responses to endothelin-1, KCl and CaCl₂, but not noradrenaline, of aortae from rats with streptozotocin-induced diabetes mellitus. *British Journal of Pharmacology*, 104(4), 928-932. <https://doi.org/10.1111/j.1476-5381.1991.tb12528.x>
- Garber, C. E., Blissmer, B., Deschenes, M. R., Franklin, B. A., Lamonte, M. J., Lee, I. M., Nieman, D. C., Swain, D. P., & American College of Sports, M. (2011). American College of Sports Medicine position stand. Quantity and quality of exercise for developing and maintaining cardiorespiratory, musculoskeletal, and neuromotor fitness in apparently healthy adults: guidance for prescribing exercise. *Medicine and Science in Sports and Exercise*, 43(7), 1334-1359. <https://doi.org/10.1249/MSS.0b013e318213fefb>
- Hall, K. E., McDonald, M. W., Grise, K. N., Campos, O. A., Noble, E. G., & Melling, C. W. (2013). The role of resistance and aerobic exercise training on insulin sensitivity measures in STZ-induced Type 1 diabetic rodents. *Metabolism*, 62(10), 1485-1494. <https://doi.org/10.1016/j.metabol.2013.05.012>
- Joshi, A., & Woodman, O. L. (2012). Increased nitric oxide activity compensates for increased oxidative stress to maintain endothelial function in rat aorta in early type 1 diabetes. *Naunyn Schmiedeberg's Archives of Pharmacology*, 385(11), 1083-1094. <https://doi.org/10.1007/s00210-012-0794-3>
- Karasu, C., & Altan, V. M. (1993). The role of endothelial cells on the alterations in vascular reactivity induced by insulin-dependent diabetes mellitus: effects of insulin treatment. *General Pharmacology*, 24(3), 743-755. <http://www.ncbi.nlm.nih.gov/pubmed/8365655>
- Keegan, A., Walbank, H., Cotter, M. A., & Cameron, N.

- E. (1995). Chronic vitamin E treatment prevents defective endothelium-dependent relaxation in diabetic rat aorta. *Diabetologia*, 38(12), 1475-1478. <http://www.ncbi.nlm.nih.gov/pubmed/8786022>
- Kiraly, M. A., Bates, H. E., Yue, J. T., Goche-Montes, D., Fediuc, S., Park, E., Matthews, S. G., Vranic, M., & Riddell, M. C. (2007). Attenuation of type 2 diabetes mellitus in the male Zucker diabetic fatty rat: the effects of stress and non-volitional exercise. *Metabolism*, 56(6), 732-744. <https://doi.org/10.1016/j.metabol.2006.12.022>
- Kobayashi, T., & Kamata, K. (1999). Effect of insulin treatment on smooth muscle contractility and endothelium-dependent relaxation in rat aortae from established STZ-induced diabetes. *British Journal of Pharmacology*, 127(4), 835-842. <https://doi.org/10.1038/sj.bjp.0702554>
- Kolluru, G. K., Bir, S. C., & Kevil, C. G. (2012). Endothelial dysfunction and diabetes: effects on angiogenesis, vascular remodeling, and wound healing. *International Journal of Vascular Medicine*, 2012. <https://doi.org/10.1155/2012/918267>
- Kregel, K. C. (2006). Resource book for the design of animal exercise protocols. American Physiological Society.
- Leo, C. H., Joshi, A., & Woodman, O. L. (2010). Short-term type 1 diabetes alters the mechanism of endothelium-dependent relaxation in the rat carotid artery. *American Journal of Physiology Heart and Circulatory Physiology*, 299(2), H502-H511. <https://doi.org/10.1152/ajpheart.01197.2009>
- Leung, H. S., Leung, F. P., Yao, X., Ko, W. H., Chen, Z. Y., Vanhoutte, P. M., & Huang, Y. (2006). Endothelial mediators of the acetylcholine-induced relaxation of the rat femoral artery. *Vascular Pharmacology*, 44(5), 299-308. <https://doi.org/10.1016/j.vph.2006.01.010>
- Minami, A., Ishimura, N., Harada, N., Sakamoto, S., Niwa, Y., & Nakaya, Y. (2002). Exercise training improves acetylcholine-induced endothelium-dependent hyperpolarization in type 2 diabetic rats, Otsuka Long-Evans Tokushima fatty rats. *Atherosclerosis*, 162(1), 85-92. [https://doi.org/10.1016/s0021-9150\(01\)00685-2](https://doi.org/10.1016/s0021-9150(01)00685-2)
- Mona, M. A., & Allam, M. H. (2018). Effects of moderate exercise training and detraining on diabetic peripheral neuropathy in streptozotocin-induced diabetic rats. *Benha Medical Journal*, 35, 150-156.
- Nakos, I., Kadoglou, N. P. E., Gkeka, P., Tzallas, A. T., Giannakeas, N., Tsalikakis, D. G., Katsimpoulas, M., Mantziaras, G., Kostomitsopoulos, N., Liapis, C. D., & Kakisis, J. (2018). Exercise training attenuates the development of cardiac autonomic dysfunction in diabetic rats. *In Vivo*, 32(6), 1433-1441. <https://doi.org/10.21873/invivo.11396>
- Oyama, Y., Kawasaki, H., Hattori, Y., & Kanno, M. (1986). Attenuation of endothelium-dependent relaxation in aorta from diabetic rats. *European Journal of Pharmacology*, 132(1), 75-78. [https://doi.org/10.1016/0014-2999\(86\)90013-0](https://doi.org/10.1016/0014-2999(86)90013-0)
- Ratamess, N. A., Alvar, B. A., Evetoch, T. E., Housh, T. J., Kibler, W. B., Kraemer, W. J., & Triplett, T. (2009). American College of Sports Medicine position stand. Progression models in resistance training for healthy adults. *Medicine and Science in Sports and Exercise*, 41(3), 687-708. <https://doi.org/10.1249/MSS.0b013e3181915670>
- Taylor, P. D., McCarthy, A. L., Thomas, C. R., & Poston, L. (1992). Endothelium-dependent relaxation and noradrenaline sensitivity in mesenteric resistance arteries of streptozotocin-induced diabetic rats. *British Journal of Pharmacology*, 107(2), 393-399. <https://doi.org/10.1111/j.1476-5381.1992.tb12757.x>
- Taylor, P. D., Oon, B. B., Thomas, C. R., & Poston, L. (1994). Prevention by insulin treatment of endothelial dysfunction but not enhanced noradrenaline-induced contractility in mesenteric resistance arteries from streptozotocin-induced diabetic rats. *British Journal of Pharmacology*, 111(1), 35-41. <https://doi.org/10.1111/j.1476-5381.1994.tb14020.x>
- Tonoli, C., Heyman, E., Roelands, B., Buyse, L., Cheung, S. S., Berthoin, S., & Meeusen, R. (2012). Effects of different types of acute and chronic (training) exercise on glycaemic control in type 1 diabetes mellitus: a meta-analysis. *Sports Medicine*, 42(12), 1059-1080. <https://doi.org/10.2165/11635380-000000000-00000>
- Torgan, C. E., Brozinick, J. T., Jr., Banks, E. A., Cortez, M. Y., Wilcox, R. E., & Ivy, J. L. (1993). Exercise training and clenbuterol reduce insulin resistance of obese Zucker rats. *American Journal of Physiology*, 264(3 Pt 1), E373-379. <https://doi.org/10.1152/ajpendo.1993.264.3.E373>
- Turgut, N. H., Temiz, T. K., Bagcivan, I., Turgut, B., Gulturk, S., & Karadas, B. (2008). The effect of sildenafil on the altered thoracic aorta smooth muscle responses in rat pre-eclampsia model. *European Journal of Pharmacology*, 589(1-3), 180-187. <https://doi.org/10.1016/j.ejphar.2008.04.034>
- Ünsal, C., & Ünsal, H. (2016). Tip I diyabetik sıçanlarda yüzme egzersizinin lipid profili ve oksidan-antioksidan duruma etkisi. *Fırat Üniversitesi Sağlık Bilimleri Dergisi*, 30(3), 119-123.
- Ünsal, H., Ünsal, C., Üner, A. G., Koç Yıldırım, E., Balkaya, M., & Belge, F. (2017). The effects of swimming exercise and probiotic VSL#3 on zonulin and some inflammatory and oxidative parameters in rats. *Kafkas Üniversitesi Veteriner Fakültesi Dergisi*, 23(1), 101-107. <https://doi.org/10.9775/kvfd.2016.15949>
- Wang, R., Wu, Y., Tang, G., Wu, L., & Hanna, S. T. (2000). Altered L-type Ca(2+) channel currents in vascular smooth muscle cells from experimental diabetic rats. *American Journal of Physiology-Heart and Circulatory Physiology*, 278(3), H714-722. <https://doi.org/10.1152/ajpheart.2000.278.3.H714>
- Yardley, J. E., Kenny, G. P., Perkins, B. A., Riddell, M. C., Balaa, N., Malcolm, J., Boulay, P., Khandwala, F., & Sigal, R. J. (2013). Resistance versus aerobic exercise: acute effects on glycemia in type 1 diabetes. *Diabetes Care*, 36(3), 537-542. <https://doi.org/10.2337/dc12-0963>

Molecular detection of deformed wing virus, black queen cell virus in honey bees in balıkesir province

Zeynep Karapınar¹, Mehmet Özüüçli²

¹Department of Virology, Faculty of Veterinary Medicine, Balıkesir University, Balıkesir, Türkiye

²Department of Parasitology, Faculty of Veterinary Medicine, Balıkesir University, Balıkesir, Türkiye

Key Words:

apis mellifera
black queen cell virus
RT-PCR
Varroa destructor

Received : 29 February 2024
Revised : 21 March 2024
Accepted : 22 April 2024
Published : 12 June 2024
Article Code : 1444999

Correspondence:

Z. KARAPINAR
(zeynepkarapinar@gmail.com)

ORCID

Z. KARAPINAR : 0000-0002-2743-8948
M. ÖZÜÜÇLİ : 0000-0003-3415-2582

ABSTRACT

Viral infections are among the risk factors affecting the health of honey bees, which are economically and ecologically important insects. These infections cause large-scale colony losses. The primary threat to the well-being of western honey bees (*Apis mellifera*) is the ectoparasitic mite *Varroa destructor*, mainly because of its role as a transmitter of viruses. This study aimed to investigate the presence of deformed wing virus (DWV) and black queen cell virus (BQCV) infections, which cause significant colony losses in honey bees, using the reverse transcriptase polymerase chain reaction (RT-PCR) method. For this purpose, adult bees were taken from 50 hives by random sampling in three different regions of Balıkesir. As a result of the analysis of the samples, the genome positivity of DWV and BQCV infections was determined to be 86% (43/50) and 24% (12/50), respectively. In the study's bee colonies, multiple infections with both viruses were found at a rate of 18% (9/50). The results obtained revealed that *Varroa* was not effectively controlled in the colonies, especially in the last month of spring, and accordingly, that viral diseases may occur due to *Varroa* infestation in the winter months.

INTRODUCTION

Honey bee farming plays an important role throughout the world in terms of the sustainability of biodiversity and agricultural production. Bees serve as essential pollinators with significant agronomic, environmental, and commercial value (Khalifa et al., 2021). Honey bees (*Apis mellifera* L.) are very important economically due to their pollinating role, which helps balance the ecosystem, bee products (honey, beeswax, royal jelly, pollen, propolis) and the use of these products in apitherapy (Kalayci et al., 2020). Multiple factors may affect bee health, whether alone or in combination (Woodford et al., 2023). Factors that threaten the health of the honey bee colony include viruses, parasites, bacteria, fungi, pesticides and poor nutrition (Usta & Yildirim, 2020). Viruses reduce the productivity of a colony by causing anomalies in organs and disorders in the immune system. Transmission of viruses in honey bees occurs horizontally or vertically. Vertical transmission occurs when viruses pass from the queen bee to the egg or from the drone to the semen. Horizontal transmission occurs between bees directly (through consumption of feces and contaminated food, cleaning activities, etc.) or through mechanical or biological vectors (de Miranda & Fries, 2008). Problems with beekeeper management or parasites, such as *Varroa destructor*, that lower host immunity or serve as a vector for various viruses can result in morbidities (Smele et al., 2023).

Since the first honey bee virus was detected in bees in 1913, 26 bee viruses have been identified (Usta & Yildirim, 2020). The most important viral infections that threaten honey bee

colonies include deformed wing virus (DWV) and black queen cell virus (BQCV).

DWV (Ifavirus aladeformis) is a member of the Ifavirus genus within the *Ifaviridae* family. It was initially discovered in Japan and subsequently detected extensively worldwide. The virion, which has a positive-strand RNA genome, is approximately 30 nm in diameter, non-enveloped and has an icosahedral symmetric structure (Lanzi et al., 2006; ICTV, 2022). The virus has a large RNA genome. While DWV follows an asymptomatic course in healthy colonies, it causes individual deaths as well as a decrease in the colony population in weaker colonies. It has been reported that stress factors, insecticides, malnutrition and *Varroa* infestation are among the predisposing factors for infection (Nazzi & Pennacchio, 2018). DWV causes clinical findings including characteristic wing deformities such as shrunk and wrinkled wings, paralysis, abdominal distension, discoloration and rapid death in honey bees (Lanzi et al., 2006).

BQCV (Triatovirus nigereginacellulae) is the second most common infection in honey bees and was first isolated from dead queen larvae and cell-sealed pupae. The causative agent is a non-enveloped, icosahedral symmetrical, single-stranded RNA virus belonging to the Triatovirus genus of the *Dicistroviridae* family (Leat et al., 2000; ICTV, 2022). Thickening and a pale yellow color in the cell wall of larvae and pupae, death in queen bee larvae, diarrhea in adult bees, edema in the intestines and enlarged abdomen are signs of infection. BQCV infection generally occurs subclinically in worker bees. It has been determined that the *Nosema apis* parasite transmits

the infection, and it is thought that *V. destructor* may also play a role in transmission (Karapinar et al., 2018).

The *Varroa* genus, which includes several species, is the cause of varroosis, a disease that affects honey bees. Some of these species are well-known, while others are overlooked and may pose a threat to apiculture. The primary species belonging to the *Varroa* genus include *V. jacobsoni*, *V. rindereri*, *V. underwoodi* and *V. destructor* (Hua et al., 2023). *V. destructor* is a severe danger to apiculture. With the exception of Australia, this mite is found all over the world, causing direct losses as well as transferring infections (such as DWV) that cause overwinter mortality. *V. destructor* is also a carrier for a number of viruses, particularly Kashmir bee virus (KBV), Sacbrood virus (SBV), acute bee paralysis virus (ABPV), Israeli acute paralysis virus (IAPV), and DWV (Shojaei et al., 2023).

This study used reverse transcriptase polymerase chain reaction (RT-PCR) to assess the incidence of DWV and BQCV infections, which can lead to considerable colony losses, in honey bee colonies in Balıkesir province.

MATERIALS and METHODS

Samples for the study were collected from beekeeping hives in various districts of Balıkesir province in February 2024. Sampling was carried out in the center of Balıkesir (Kabakdere) and two districts in the south (Sındırgı and Bigadiç). There were 65 bee colonies in the first apiary, 50 in the second apiary and 60 in the third apiary. Adult honey bee samples were taken randomly from 50 colonies: 25 in Kabakdere, 15 in Sındırgı, and 10 in Bigadiç. A total of 30 adult honey bees from the outermost frame of each hive were taken into sterile containers. The samples were stored at -18°C until analyzed. *Varroa* agents were observed by inspection in all the sampled hives. The honey bee samples were stored in the laboratory for one day to ensure that the bees were unable to move.

Viral RNA Extraction

In order to extract viral RNA, 10–30 bees were taken from the same hive and processed as a single sample. The homogenate was then prepared by crushing the samples in a mortar and diluting them with phosphate-buffered saline (PBS). After the prepared homogenate was centrifuged at 4000 rpm for 10 minutes, the resulting supernatant was used for viral RNA extraction. Viral nucleic acid isolation (Viral RNA+DNA Preparation Kit, Jena Bioscience, Germany) was used to extract viral RNA in compliance with the kit's instructions.

Complementary DNA (cDNA) Synthesis and Reverse Transcriptase Polymerase Chain Reaction (RT-PCR)

A complementary DNA kit (First Strand cDNA synthesis kit, Thermo Fisher Scientific, Germany) was used to convert RNA into complementary DNA before the PCR stage. For cDNA synthesis of each sample, after preparing the first mixture, which included 3 µL of sterile distilled water, 0.5 µL of random hexamer primer and 3 µL of RNA, the tubes were put in the thermal cycler. The tubes were held at 70°C for five minutes before being put on ice. In the second stage, the tubes

holding the first mixture were filled with the second mixture, which contained 2.0 µL of 5x reaction buffer, 1.0 µL of 10 mM dNTP mix, and 0.5 µL of M-MuLV reverse transcriptase, for a total of 3.5 µL. The tubes were then incubated at 48°C for 45 minutes.

For DWV in the RT-PCR reaction forward DWV1 5'-TTTGCAAGATGCTGTATGTGG-3' and reverse DWV2 primer pair were used (Gülmez et al., 2009). For BQCV in the RT-PCR reaction forward 5'-TGGTCAGCTCCCCTACCTTAAAC-3' and 5'-GCAACAAGAAGAAACGTAAACCAC-3' primer pair were used (Benjeddou et al., 2001). A total of 30 µL PCR master mix was prepared for both PCR amplification processes. The amount of DNA it contained was 3 µL, 75 mM Tris-HCl (pH 8.8), 20 mM NH₄(SO₄)₂, 1.5 mM of MgCl₂, primers 10 pmol, 0.2 mM of dNTP. Taq DNA polymerase was prepared as 0.5 U (MBI, Fermentas, Lithuania). Controls available in the Department of Virology were used as positive controls. For DWV, following a 6-minute denaturation phase at 95°C, 30 seconds at 95°C, 60 seconds at 54°C, and 30 seconds at 72°C were applied, and this heat program was repeated for 35 cycles. Finally, a 7-minute, 68°C extension was used to finish the procedure. The heat program for BQCV was performed 40 times, with 30 seconds at 95°C, 60 seconds at 55°C, and 120 seconds at 68°C applied after a 2-minute denaturation phase at 95°C. A final 7-minute extension at 68°C brought the procedure to a completion. A 100 bp DNA marker was used for evaluation, and the amplified DNA products were detected in the gel imaging device under UV light after being dyed with safe view dye in 1.5% agarose gel.

Varroa agents were observed by inspection in all sampled hives. The honey bee samples were stored in the laboratory at -18°C for one day to ensure that the bees were unable to move.

RESULTS

The study samples were collected from beekeeping hives in various parts of Balıkesir province. When the study results were examined, DWV was found in all studied bee colonies. While 43 of the 50 (86%) apiaries sampled were determined to be positive for DWV, 12 (24%) were determined positive for BQCV (Table 1). In the study's bee colonies, multiple infections with both viruses were found at a rate of 18% (9/50). Three separate apiary samplings were conducted: one from the Central province (Kabakdere), one from Sındırgı, and one from the Bigadiç. DWV was detected as 88% (22/25) in the first apiary, 86.6% (13/15) in the second apiary, and 80% (8/10) in the third apiary. BQCV was detected as 28% (7/25) in the first apiary, 13.3% (2/15) in the second apiary, 3% (3/10) in the third apiary. The regions from where the samples were taken are shown in Figure 1.

In the study, DWV was detected using RT-PCR with primers for the particular polyprotein gene, and a 395 bp region was amplified (Figure 2). The presence of BQCV was tested using RT-PCR primers for the particular structural polyprotein gene, which amplified a 700 bp region (Figure 23). The *Varroa* agent on the live bee is shown in Figure 4.

Table 1. DWV, BQCV RT-PCR positivity rates according to the sampled regions.

Code	Sampling location	Number of hives examined	Number of hives in the apiary	DWV	BQCV	DWV BQCV
1	Central province (Kabakdere)	25	65	22 (88%)	7 (28%)	6 (24%)
2	Sındırgı	15	50	13 (86.6%)	2 (13.3%)	1 (6.6%)
3	Bigadiç	10	60	8 (80%)	3 (3%)	2 (20%)
Total	50		175	43 (86%)	12 (24%)	9 (18%)

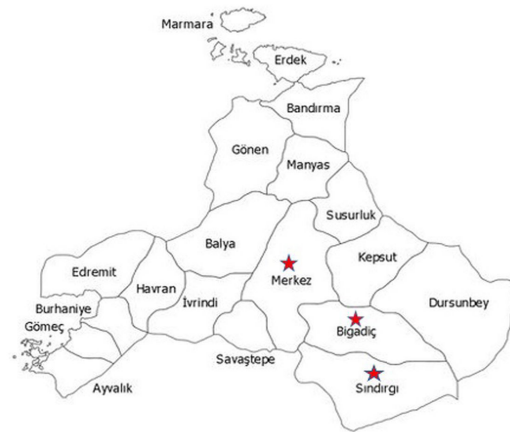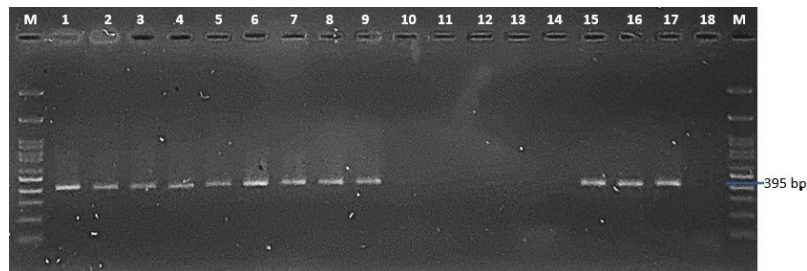
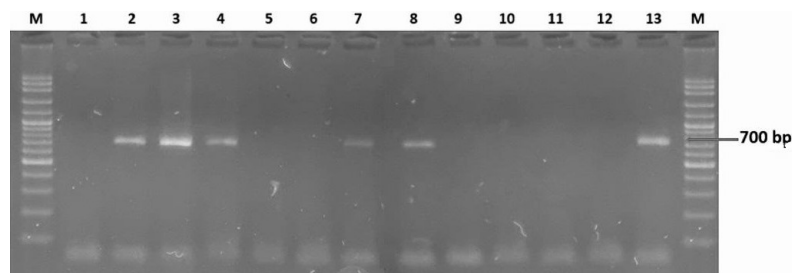
**Figure 1.** Distribution of beekeeping regions sampled in Balıkesir province**Figure 2.** PCR amplification products using DWV primers. Lane M: 100-bp DNA ladder marker (Fermentas); lanes 1-9, 15, 16: positive amplification PCR products, lanes 10-14: negative amplification PCR products.; lane 17: positive control; lane 18: negative control (distilled water)**Figure 3.** PCR amplification products using BQCV primers. Lane M: 100-bp DNA ladder marker (Fermentas); lane 1: negative control (distilled water), lane 2: positive control; lanes 3, 4, 7, 8, 13: positive amplification PCR products; lanes 5, 6, 9-12: negative amplification PCR products



Figure 4. *Varroa* agent on the live bee shown with a yellow arrow (original)

DISCUSSION

Beekeeping plays a significant economic role in all countries worldwide. Considering Türkiye's rich environment of plant flora and fauna, the results of the present study are due to a lack of effective hive and colony management, as well as insufficient measures taken to combat parasitic, bacterial, and viral infections. Recently, a number of studies have revealed the high rates of colony collapse in honey bees, which has significant implications for the conservation of biodiversity (Tang et al., 2023).

DWV is one of the most common honey bee viruses in the world. In studies conducted in different parts of the world, the prevalence of infection has been reported as 97%, 91%, 95%, 72% and 97% in Austria, Croatia, Hungary, Denmark and France, respectively (Amiri et al., 2015; Berényi et al., 2006; Forgách et al., 2008; Tentcheva et al., 2004; Tlak Gajger et al., 2014). BQCV has been reported at very different rates in different regions of the world, with a prevalence of 91%, 86%, 65% and 81% in Uruguay, France, Australia and Chile, respectively (Antúnez et al., 2006; Roberts et al., 2017; Rodríguez et al., 2012; Tentcheva et al., 2004).

Numerous studies on viral infections of honey bees have been carried out in various regions of Türkiye. The virus was widely detected in all bee farms sampled in seven different districts of Hatay province (Muz & Muz, 2009). The presence of DWV in Ordu was detected by RT-PCR using primers for the specific polyprotein gene (Gülmez et al., 2009). Studies conducted in our country generally aim to investigate more than one viral agent in honey bees. DWV and BQCV infections are among the most common viral infections. In a study investigating three different viruses in honey bees in the Black Sea region, the presence of chronic bee paralysis virus (CBPV) was determined as 25%, the presence of BQCV was determined as 21.42%, while acute bee paralysis virus (ABPV) was not detected (Gumusova et al., 2010). In a study investigating four different viruses in Van province,

DWV positivity was found to be 69.23% and BQCV positivity was 88.46%; ABPV and CBPV were not detected in the hives sampled in the same study (Karapinar et al., 2018). In a study in which DWV, BQCV and ABPV infections in different bee breeds were studied using the RT-PCR method in random sampling from 31 hives in 15 bee farms located in very different regions, the prevalence of these diseases was determined as 74.19%, 25.81% and 74.19%, respectively (Usta & Yildirim, 2022). In research on DWV, ABPV and BQCV in Burdur province, DWV and ABPV were found in 13 of the 15 apiaries studied, while BQCV was detected in 8 of 11 apiaries (Cagiran et al., 2020). In a study investigating the main factors causing colony losses, the prevalence of DWV, ABPV, BQCV, SBV, CBPV and IAPV was determined as 44.7%, 35.5%, 28.9%, 22.3%, 18.4% and 6.5%, respectively (Kalayci et al., 2020). In a study investigating apiaries located in many provinces in the Aegean region, 111 hives were sampled and DWV, BQCV, ABPV, SBV, CBPV positivity was found to be 19.8%, 18%, 3.6%, 2.7% and 1.8%, respectively (Çağiran & Yazici, 2021). In the present study, DWV positivity was determined as 86% (43/50) and BQCV positivity was determined as 24% (12/50).

Viral bee diseases reduce bee productivity, causing a direct impact on bee colony losses and thus the yield of bee products. In colonies affected by DWV, wingless bees are observed and the fertility of the queen bee decreases. Furthermore, weak bee colonies spread infections and lead to transmission of disease inside the colony. DWV can be transmitted through semen and eggs, both fertile and unfertile, and transmitted vertically to subsequent generations (de Miranda & Fries, 2008). In this study, it was observed that the viral genome positivity rate was quite high in the hives sampled. Winter conditions can be more difficult for honey bees in temperate climates, resulting in winter losses in honey bee colonies that cannot survive the season. While the reason for these losses may be other natural causes, viral infections and *Varroa* infestation have been documented to exacerbate this situation (Francis et al., 2013). In the present study, these viral infections, especially

DWV, were detected quite frequently. It is thought that the fact that the sampling was carried out in winter contributed to this result.

Studies have shown that BQCV epidemiology is related to the *Nosema* parasite. It has been revealed that the presence of the virus increases with the intensification of *Nosema* infestation, especially in the summer months when the temperature increases (Berényi et al., 2006; Oguz et al., 2017; Tentcheva et al., 2004). From this information, it is possible that one of the reasons why the density of BQCV was lower than that of DWV in the present study was that the sampling was conducted during the winter.

Results obtained from field data have demonstrated that the *Varroa* mite is a very effective vector for DWV and haven shown that when the virus changes host, it becomes more virulent in bees infected with *V. destructor*. The degree of virus concentration in infected colonies is positively correlated with *Varroa* infestation, and it has been found that the *Varroa* mite is not only a carrier but also an activator of viral replication in honey bees. Furthermore, parasitism lowers bee immunity, which promotes virus proliferation (Chen et al., 2005). *Varroa* recently moved to the western honeybee (*A. mellifera*) from its natural host, *A. cerana*. The host-parasite relationship in *A. mellifera* is not yet balanced. Nonetheless, it may be expected that a steady coexistence between the parasite and host will develop over time (Fanelli & Tizzani, 2020). The parasite directly harms the colony, resulting in fewer swarms, which has a financial impact on beekeepers. Furthermore, colonies with parasitic mite syndrome may exhibit scattered brood, crawling, and crippled bees. The spillover to wild pollinators raises further concerns. The life period of the mite varies based on humidity and temperature, ranging from a few days to several months. Clinical signs typically appear in the later stages of an infestation, with the peak of the infestation occurring later in the season (Gela et al., 2023). It has been noted that the main reason why varroosis is so common in our country is that migratory beekeeping is conducted in an uncontrolled manner and beekeepers are unaware of the mite's transmission, biology and control (Gülmez et al., 2009). The same results were obtained from the present study, and it seems that the current measures taken to fight *Varroa* mites are not sufficient.

DWV and IAPV, in particular, have an effect on learning and memory, causing foragers to lose orientation and wander to surrounding colonies. The process allows both viruses and mites to disperse (Li et al., 2013). In the light of this information, combating DWV, which is known to have a significant effect and is widely detected in bee colonies, is of vital importance in the beekeeping sector. It is necessary to effectively fight against infections to prevent colony losses and ensure the continued health of the beekeeping industry.

CONCLUSION

Viral agents that cause infection in honey bees pose a substantial threat because they are difficult to diagnose, have no treatment, and are more easily contagious. Due to the lack of proper *Varroa* control, serious bee colony losses are experienced both in Türkiye and worldwide.

Preventing or minimizing unexplained colony losses, especially in beehives, is essential for the future and continuation of the beekeeping industry. Balıkesir province is currently experiencing an increase in the number of honey bee farms due to its favorable temperature and geography. In the present study, updated data on DWV and BQCV in the Balıkesir region were obtained, and it is thought that this will form the basis for new research on viral infections in honey bees in the region. In order to prevent colony losses, ensure the continuance of bee breeding and bee products, detailed studies on bee viruses need to be carried out in order to determine the causes of viral infections in bees and to obtain more information about the epidemiology, genetics and pathogenesis of infections.

DECLARATIONS

Ethics Approval

It has been reported that the Approval of the Local Ethics Committee for Animal Experiments is not required for the study, in accordance with the provisions of Article 4.1 (d) of the 'Regulation on Working Procedures and Principles of Animal Committees' published in the Official Gazette No. 28914 on 15.02.2014.

Conflict of Interest

The authors declared that there is no conflict of interest.

Consent for Publication

Not applicable.

Competing Interest

The authors declare that they have no competing interests.

Author contribution

Idea, concept and design: ZK, MÖ

Data collection and analysis: MÖ, ZK

Drafting of the manuscript: ZK, MÖ

Critical review: ZK, MÖ

Data Availability

Not applicable.

Acknowledgments

Not applicable.

REFERENCES

- Amiri, E., Meixner, M., Nielsen, S. L., & Kryger, P. (2015). Four categories of viral infection describe the health status of honey bee colonies. *PLoS ONE*, 10(10), 10–12. <https://doi.org/10.1371/journal.pone.0140272>
- Antúnez, K., D'Alessandro, B., Corbella, E., Ramallo, G., & Zunino, P. (2006). Honeybee viruses in Uruguay. *Journal of Invertebrate Pathology*, 93(1), 67–70. <https://doi.org/10.1016/j.jip.2006.05.009>
- Benjeddou, M., Leat, N., Allsopp, M., & Davison, S. (2001). Detection of Acute Bee Paralysis Virus and Black Queen Cell Virus from Honeybees by Reverse Transcriptase PCR. *Applied and Environmental Microbiology*, 67(5), 2384–2387. <https://doi.org/10.1128/AEM.67.5.2384-2387.2001>

doi.org/10.1128/AEM.67.5.2384-2387.2001

Berényi, O., Bakonyi, T., Derakhshifar, I., Köglberger, H., & Nowotny, N. (2006). Occurrence of six honeybee viruses in diseased Austrian apiaries. *Applied and Environmental Microbiology*, 72(4), 2414–2420. <https://doi.org/10.1128/AEM.72.4.2414-2420.2006>

Çağırzan, A. A., & Yazici, Z. (2021). The prevalence of seven crucial honeybee viruses using multiplex RT-PCR and their phylogenetic analysis. *Turkish Journal of Veterinary and Animal Sciences*, 45(1), 44–55. <https://doi.org/10.3906/VET-2004-139>

Cagırgan, A. A., Yildirim, Y., & Usta, A. (2020). Phylogenetic analysis of deformed wing virus, black queen cell virus and acute bee paralysis viruses in Turkish honeybee colonies. *Medycyna Weterynaryjna*, 76(8), 480–484. <https://doi.org/10.21521/mw.6437>

Chen, Y., Pettis, J. S., & Feldlaufer, M. F. (2005). Detection of multiple viruses in queens of the honey bee *Apis mellifera* L. *Journal of Invertebrate Pathology*, 90(2), 118–121. <https://doi.org/10.1016/j.jip.2005.08.005>

de Miranda, J. R., & Fries, I. (2008). Venereal and vertical transmission of deformed wing virus in honeybees (*Apis mellifera* L.). *Journal of Invertebrate Pathology*, 98(2), 184–189. <https://doi.org/10.1016/j.jip.2008.02.004>

Fanelli, A., & Tizzani, P. (2020). Spatial and temporal analysis of varroosis from 2005 to 2018. *Research in Veterinary Science*, 131(January), 215–221. <https://doi.org/10.1016/j.rvsc.2020.04.017>

Forgách, P., Bakonyi, T., Tapaszt, Z., Nowotny, N., & Rusvai, M. (2008). Prevalence of pathogenic bee viruses in Hungarian apiaries: Situation before joining the European Union. *Journal of Invertebrate Pathology*, 98(2), 235–238. <https://doi.org/10.1016/j.jip.2007.11.002>

Francis, R. M., Nielsen, S. L., & Kryger, P. (2013). Varroa-Virus Interaction in Collapsing Honey Bee Colonies. *PLoS ONE*, 8(3). <https://doi.org/10.1371/journal.pone.0057540>

Gela, A., Atickem, A., Bezabeh, A., Woldehawariat, Y., & Gebresilassie, A. (2023). Insights into varroa mite (*Varroa destructor*) infestation levels in local honeybee (*Apis mellifera*) colonies of Ethiopia. *Journal of Applied Entomology*, 147(9), 798–808. <https://doi.org/10.1111/jen.13171>

Gülmez, Y., Bursali, A., & Tekin, Ş. (2009). First molecular detection and characterization of deformed wing virus (DWV) in honeybees (*Apis mellifera* L.) and mite (*Varroa destructor*) in Turkey. *African Journal of Biotechnology*, 8(16), 3698–3702.

Gumusova, S. O., Albayrak, H., Kurt, M., & Yazici, Z. (2010). Prevalence of three honey bee viruses in Turkey. *Veterinarski Arhiv*, 80(6), 779–785.

Hua, T., Chantawannakul, P., Tsai, C. L., & Yeh, W. Bin. (2023). Genetic Profile of the Parasitic Varroan Mite *Varroa destructor* (Arachnida: Mesostigmata: Varroidae) in Taiwan: a

New Taiwanese Haplotype Intermediate Between the Highly Virulent Russian and Less Virulent Japanese Types Identified in the Honey Bee Host *Ap. Zoological Studies*, 62, 1–12. <https://doi.org/10.6620/ZS.2023.62-11>

ICTV. (2022). International Committee on Taxonomy of Viruses. Available at <https://ictv.global/taxonomy/>. Date of Access: 24.04.2024

Kalayci, G., Cagırgan, A. A., Kaplan, M., Pekmez, K., Beyazit, A., Ozkan, B., Yesiloz, H., & Arslan, F. (2020). The role of viral and parasitic pathogens affected by colony losses in Turkish apiaries. *Kafkas Universitesi Veteriner Fakultesi Dergisi*, 26(5), 671–677. <https://doi.org/10.9775/kvfd.2020.24154>

Karapınar, Z., Özüz, B., Dinçer, E., & Öztürk, C. (2018). Phylogenetic analysis of black queen cell virus and deformed wing virus in honeybee colonies infected by mites in Van, Eastern Turkey. *Medycyna Weterynaryjna*, 74(7), 460–465. <https://doi.org/10.21521/mw.5990>

Khalifa, S. A. M., Elshafey, E. H., Shetaia, A. A., El-Wahed, A. A. A., Algethami, A. F., Musharraf, S. G., Alajmi, M. F., Zhao, C., Masry, S. H. D., Abdel-Daim, M. M., Halabi, M. F., Kai, G., Al Naggar, Y., Bishr, M., Diab, M. A. M., & El-Seedi, H. R. (2021). Overview of bee pollination and its economic value for crop production. *Insects*, 12(8), 1–23. <https://doi.org/10.3390/insects12080688>

Lanzi, G., de Miranda, J. R., Boniotti, M. B., Cameron, C. E., Lavazza, A., Capucci, L., Camazine, S. M., & Rossi, C. (2006). Molecular and Biological Characterization of Deformed Wing Virus of Honeybees (*Apis mellifera* L.). *Journal of Virology*, 80(10), 4998–5009. <https://doi.org/10.1128/jvi.80.10.4998-5009.2006>

Leat, N., Ball, B., Govan, V., & Davison, S. (2000). Analysis of the complete genome sequence of black queen-cell virus, a picorna-like virus of honey bees. *Journal of General Virology*, 81(8), 2111–2119. <https://doi.org/10.1099/0022-1317-81-8-2111>

Li, Z., Chen, Y., Zhang, S., Chen, S., Li, W., Yan, L., Shi, L., Wu, L., Sohr, A., & Su, S. (2013). Viral Infection Affects Sucrose Responsiveness and Homing Ability of Forager Honey Bees, *Apis mellifera* L. *PLoS ONE*, 8(10), 1–10. <https://doi.org/10.1371/journal.pone.0077354>

Muz, D., & Muz, M. N. (2009). Survey of the occurrence of deformed wing virus and multiple parasites of queens (*Apis mellifera* L.) in apiaries with collapsed colonies in Hatay, Turkey. *Journal of Apicultural Research*, 48(3), 204–208. <https://doi.org/10.3896/IBRA.1.48.3.09>

Nazzi, F., & Pennacchio, F. (2018). Honey bee antiviral immune barriers as affected by multiple stress factors: A novel paradigm to interpret colony health decline and collapse. *Viruses*, 10(4). <https://doi.org/10.3390/v10040159>

Oguz, B., Karapınar, Z., Dinçer, E., & Değer, M. S. (2017). Molecular detection of Nosema spp. and black queen-cell virus in honeybees in Van Province, Turkey. *Turkish Journal of Veterinary and Animal Sciences*, 41(2), 221–227. <https://doi.org/10.15187/tjvas.2017.41.2.221>

doi.org/10.3906/vet-1604-92

Roberts, J. M. K., Anderson, D. L., & Durr, P. A. (2017). Absence of deformed wing virus and Varroa destructor in Australia provides unique perspectives on honeybee viral landscapes and colony losses. *Scientific Reports*, 7, 6925. <https://doi.org/10.1038/s41598-017-07290-w>

Rodríguez, M., Vargas, M., Gerding, M., Navarro, H., & Antúnez, K. (2012). Viral infection and Nosema ceranae in honey bees (*Apis mellifera*) in Chile. *Journal of apicultural research*, 51, 285-287. <https://doi.org/10.3896/IBRA.1.51.3.12>

Shojaei, A., Nourian, A., Khanjani, M., & Mahmoodi, P. (2023). The first molecular characterization of Lake Sinai virus in honey bees (*Apis mellifera*) and Varroa destructor mites in Iran. *Journal of Apicultural Research*, 62(5), 1176–1182. <https://doi.org/10.1080/00218839.2021.1921467>

Smeele, Z. E., Baty, J. W., & Lester, P. J. (2023). Effects of Deformed Wing Virus-Targeting dsRNA on Viral Loads in Bees Parasitised and Non-Parasitised by Varroa destructor. *Viruses*, 15(11). <https://doi.org/10.3390/v15112259>

Tang, J., Ji, C., Shi, W., Su, S., Xue, Y., Xu, J., Chen, X., Zhao, Y., & Chen, C. (2023). Survey Results of Honey Bee Colony Losses in Winter in China (2009–2021). *Insects*, 14(6), 1–18. <https://doi.org/10.3390/insects14060554>

Tentcheva, D., Gauthier, L., Zappulla, N., Dainat, B., Cousserans, F., Colin, M. E., & Bergoin, M. (2004). Prevalence and seasonal variations of six bee viruses in *Apis mellifera* L. and Varroa destructor mite populations in France. *Applied and Environmental Microbiology*, 70(12), 7185–7191. <https://doi.org/10.1128/AEM.70.12.7185-7191.2004>

Tlak Gajger, I., Kolodziejek, J., Bakonyi, T., & Nowotny, N. (2014). Prevalence and distribution patterns of seven different honeybee viruses in diseased colonies: a case study from Croatia. *Apidologie*, 45(6), 701–706. <https://doi.org/10.1007/s13592-014-0287-0>

Usta, A., & Yildirim, Y. (2022). Investigation of deformed wing virus, black queen cell virus, and acute bee paralysis virus infections in honey bees using reverse transcriptase-polymerase chain reaction (RT-PCR) method. *Ankara Üniversitesi Veteriner Fakültesi Dergisi*, 69(3), 303–311. <https://doi.org/10.33988/aufvd.824882>

Usta, A., & Yıldırım, Y. (2020). Bal Arılarının Viral Hastalıkları. *Cukurova University, Agriculture Faculty*, 1(35), 57–66. <https://doi.org/10.36846/cjafs.2020.18>

Woodford, L., Sharpe, G., Highet, F., & Evans, D. J. (2023). All together now: Geographically coordinated miticide treatment benefits honey bee health. *Journal of Applied Ecology*, 60(5), 790–802. <https://doi.org/10.1111/1365-2664.14367>

Molecular detection of feline calicivirus (FCV) in cats with oral lesions

Hasbi Sait Saltık¹, Zehra Erdağı²

¹Department of Virology, Faculty of Veterinary Medicine, Burdur Mehmet Akif Ersoy University, Burdur, Türkiye

²Faculty of Veterinary Medicine, Burdur Mehmet Akif Ersoy University, Burdur, Türkiye

Key Words:

calicivirus
feline
oral lesions
respiratory tract disease
RT-PCR

Received : 29 February 2024
Revised : 22 April 2024
Accepted : 23 April 2024
Published : 12 June 2024
Article Code : 1445360

Correspondence:

HS. SALTİK
(hasbi.saltik@gmail.com)

ORCID

HS. SALTİK : 0000-0003-1691-7764
Z. ERDAĞI : 0000-0001-7838-2553

We gratefully acknowledge the support of TUBİTAK, which provided financing for the research (2209. Project Number: 1919B012112850).

ABSTRACT

Feline Calicivirus (FCV) is a major cause of oral lesions in cats with respiratory tract disease (RTD). FCV is a single-stranded, positive-polarity RNA virus that encodes three open reading frames (ORFs). Active virus excretion occurs through the saliva of cats infected with FCV, which belongs to the *Vesivirus* genus of the *Caliciviridae* family. Oral mucosal lesions caused by infectious agents in RTD lead to significant impairment in the quality of life of cats. RTD, which also affects the oral mucosa, is a common problem in cats. Ten cats of different ages, breeds, and genders with ocular lesions were used in this study. At the time of sample collection, the veterinarian performed general and oral examinations on each animal. On oral examination, varying degrees of gingivitis, stomatitis, and ulceration symptoms were noted. Samples were extracted using a commercial viral nucleic acid isolation kit. Three out of ten samples (30%) were found to be positive for FCV using RT-PCR. In conclusion, the high sensitivity, specificity, and potential for field sample testing make RT-PCR a very important and inevitable method for research and clinical diagnosis related to FCV infection in cats with oral lesions.

INTRODUCTION

Viral infections in cats represent a significant concern due to their potential impact on various systems. The ability of these infections to target multiple systems, including the digestive, respiratory, immune, genital, and neural systems, underscores the complexity and severity of viral diseases in cats (Aydın and Timurkan 2018; Baydar et al. 2014; Karapinar et al. 2024). In recent years, respiratory tract disease (RTD), which also affects the oral mucosa, has been increasingly encountered in cats among these infections (Dağalp et al. 2019; Lee et al. 2019; Schulz et al. 2015). Oral mucosal lesions caused by infectious agents in RTD lead to a significant deterioration in cats' quality of life. In addition, mixed infections with more than one pathogen pose difficulties for veterinarians in terms of diagnosis and treatment methods (Sykes et al. 1997; Cao et al. 2022). The primary pathogens that appear in mixed cases are Feline calicivirus (FCV) feline herpesvirus-1 (FHV-1), *Bordetella bronchiseptica*, *Chlamydia psittaci*, and others. (Walter et al. 2020).

FCV is a highly contagious viral pathogen that poses a significant threat to the health of cats worldwide (Abd-Eldaim et al. 2009). Cats infected with FCV often present with a range of clinical signs, including oral lesions that can range from mild gingivitis to severe ulcerative stomatitis, causing discomfort. Detection and diagnosis of FCV in cats with oral

lesions is crucial for effective treatment and control of the disease (Cao et al. 2022; Henzel et al. 2012). Studies have shown that FCV is one of the main causes of oral lesions in cats (Fontes et al. 2023). FCV is a single-stranded, positive polarity RNA virus that encodes three open reading frames (ORFs) (Radford et al. 2007). Active virus excretion occurs via the saliva of cats infected with FCV, which belongs to the *Vesivirus* genus of the *Caliciviridae* family. This shedding can last for several months depending on individual factors (Binns et al. 2000). FCV infection has been reported to be common in housed domestic cats under one year of age and in cats living in shelters. FCV infection occurs in these cats, particularly in chronic stomatitis (Knowles et al. 1989; Fontes et al. 2023). FCV can cause cases of gingivostomatitis in cats and humans because, together with bacterial plaques, they cause lymphocyte infiltration into the oral mucosa (Lommer and Verstraete 2003). FCV, which studies have not yet shown to pose a direct threat to humans, can cause fatal illnesses in cats. The infection caused by this pathogen is particularly common in animal shelters and cat hotels and usually affects young cats. In Türkiye, many cats, including owner cats, have direct or indirect contact with stray animals. This can cause infected cats to transmit infections like FCV more easily. Since FCV, whose nucleic acid was detected in the current project, is a highly variable RNA virus, the data obtained from positive cases will help future molecular characterization studies.

The aim of this research article is to prevent the further spread of the virus and improve the welfare of cats by highlighting the value of the RT-PCR method for the detection of FCV in cats with oral lesions.

MATERIALS and METHODS

Animals and Ethics Statement.

This study used ten cats of different ages, breeds and genders with oral lesions between 2022 and 2023. They were transported to the Virology Laboratory the Faculty of Veterinary Medicine, Burdur Mehmet Akif Ersoy University Animal Hospital, and private veterinary clinics. The patients' veterinarians provided information about the cats to which each sample belonged. The animals had a variety of severe symptoms, including gingivitis, stomatitis and ulcers. The same veterinarian examined each animal and recorded its symptoms. This study was approved by the Animal Ethics Committee of

nucleic acid isolation kit (Roch, Germany). The post-extraction PCR test was performed according to the method of Ohe et al. (2006). Samples found to be positive were aliquoted and stored at -80°C until testing. An extract from a commercial vaccine containing FCV was used as a positive control in the RT-PCR test. Ultra-pure water was used as a negative control.

RESULTS

Clinical signs

A general examination of the cats showed signs of poor oral hygiene (20%), loss of appetite (100%), and reluctance to perform any oral care. After oral examinations, varying degrees of gingivitis (50%), stomatitis (10%), and ulceration (60%) symptoms were found. Overall, three out of ten (30%) cats were detected as positive using RT-PCR. All findings observed during sampling, cat information, and RT-PCR results are listed in Table 1.

Table 1. Cat data, recorded clinical observations and RT-PCR results.

No	Age/ Months	Gender	Symptoms					RT-PCR
			Poor oral hygiene	Loss of appetite	Gingivitis	Stomatitis	Ulceration	
1	6	♂	X	✓	✓	X	✓	+
2	6	♂	X	✓	X	X	✓	-
3	9	♂	X	✓	X	X	X	-
4	5	♀	✓	✓	✓	X	X	-
5	12	♂	X	✓	✓	X	X	+
6	12	♂	X	✓	X	X	✓	-
7	8	♀	X	✓	✓	X	X	-
8	24	♀	X	✓	X	X	✓	-
9	24	♀	✓	✓	X	✓	✓	+
10	12	♂	X	✓	✓	X	✓	-

”✓” marks were used for cats with symptoms and “X” marks for cats without symptoms.

Burdur Mehmet Akif Ersoy University under approval number 102/915.

Clinical signs

General and oral examinations were performed on each animal by the veterinarian at the time of sample collection. All findings observed in the cats included in the study were recorded.

Samples

Samples were collected using sterile commercial swabs dipped in PBS with antibiotics. All the liquid in the swabs was transferred to sterile 2 mL microtubes after complete vortex mixing. It was centrifuged for 20 minutes at +4 °C and 3000 rpm. After centrifugation, 500 µL of the supernatant was collected and stored at -80 °C until testing.

Nucleic acid extraction and PCR test

The supernatants were extracted using a commercial viral

DISCUSSION

Common viral infections in cats include FIP, FIV, FeHV-1, and FCV (Aydin et al. 2018; Baydar et al. 2014; Karapinar et al. 2024; Koc and Oguzoglu, 2020). These viruses can target multiple systems, including the digestive, respiratory, immune, genital, and neural systems, causing a range of symptoms such as fever, pale gums, loss of appetite or weight loss, lethargy and weakness, conjunctivitis, inflammation of the gums and mouth, and respiratory problems (Dağalp et al. 2019; Westman et al. 2022). These viral infections can have significant impacts on a cat's health and well-being, and prevention measures such as vaccination and maintaining good hygiene are crucial in minimizing the risk of infection and transmission. The most common viral pathogens that cause feline respiratory disease complex are FeHV-1 and FCV (Walter et al. 2020). These viruses are responsible for most cases of upper respiratory infections in cats and are often found in combination, with FHV-1 being the primary cause and FCV being more prevalent in some cat populations (Henzel et al. 2012). The clinical symptoms of RTD in cats are similar to those of other feline

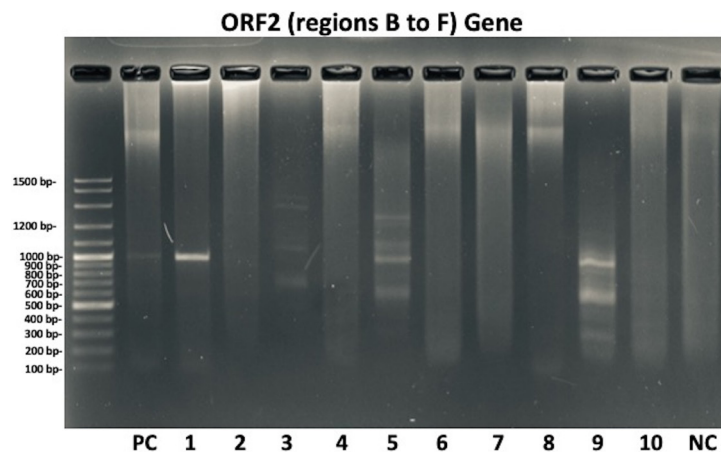


Figure 1. Agarose gel image showing the PCR results of each sample. Lane 1 (Ladder), lane 2 (Positive control), and lane 13 (Negative control) are arranged from left to right. Samples 1, 5 and 9 were positive and the others were negative based on the results of the PCR tests performed.

pathogens, including FCV (Lee et al. 2019; Schulz et al. 2015). FCV infections have become more common in cats worldwide (Mochizuki et al. 2000; Dağalp et al. 2019). A differential diagnosis of these pathogens is required for proper treatment and control (Cao et al. 2022). Diagnostic methods for FCV detection in samples include molecular detection using conventional PCR, virus isolation, and immunofluorescence antibody assay (IFA). Nevertheless, the sensitivity of antigen detection is rather low, although it is quick and inexpensive. Although it can take several days to two weeks, virus isolation is the gold standard. The sensitivity and specificity of conventional RT-PCR assays have also been shown to be high (Sykes et al., 1998). In our study, 30% of cats were found to be FCV positive using RT-PCR. The use of RT-PCR to detect FCV, particularly in cats with oral lesions, provides a valuable approach to identifying the virus and understanding its association with disease severity. These studies add to the growing body of evidence supporting the use of RT-PCR to detect and monitor FCV, particularly in cat populations affected by oral infectious diseases (Henzel et al. 2012; Palombieri et al., 2023; Weeks et al., 2001;). Studies highlight the utility of real-time PCR assays in detecting FCV in cats with stomatitis and highlight the role of molecular diagnostics in guiding targeted therapy as well as the importance of genome sequencing in understanding the genetic diversity of FCV strains (Abd-Eldaim et al., 2009; Palombieri et al., 2023; Radford et al. (2021). Using molecular methods, detection of FCV in cat populations can help identify potential sources of infection and guide targeted interventions. FCV detection in cats with oral lesions using real-time polymerase chain reaction (RT-PCR) is a sensitive and specific method (Schulz et al. 2015; Cao et al. 2022). However, several factors may influence the accuracy of RT-PCR in detecting FCV in cats with oral lesions. These factors include sampling, sensitivity, cross-contamination, genetic variability, interpretation, and cost and equipment. Obtaining high-quality samples from oral lesions can be challenging due to the presence of debris, blood, or inflammatory exudates that can interfere with the PCR process. Despite its high sensitivity, RT-PCR can still fail to detect FCV in samples with low viral loads, especially in intermittent shedding or carrier states (Henzel et

al. 2012; Schulz et al. 2015). The risk of contamination during sample processing and PCR setup can lead to false positive results, highlighting the need for strict laboratory practices to prevent contamination. FCV exhibits genetic diversity, which can create challenges in developing primers that effectively target all circulating strains, potentially leading to false-negative results. Proper interpretation of RT-PCR results requires expertise in distinguishing between active infection, carrier status, or environmental contamination to avoid misdiagnosis. RT-PCR requires specialized equipment and trained personnel, which makes it relatively expensive and less accessible compared to other diagnostic methods (Hofmann-Lehmann et al. 2022; Palombieri et al. 2023). Various interpretations based on the association between cat age and FCV infection have received attention in recent studies. While some studies suggest that younger cats are more likely to be infected with FCV due to factors such as limited access to vaccinations and impairment of maternal antibodies (Zheng et al. 2021), other research suggests that older cats are more susceptible to FCV infections (Tran et al. 2019). One study found that age was significantly associated with FCV transmission and cats older than 3 years were less likely to transmit the virus (Coyne et al., 2006). It has also been reported that kittens less than 8 weeks of age entering shelters were not exposed to FCV, but the transmission rate of the virus increased with age and the highest transmission rate was found in kittens and young cats (Pedersen et al., 2004). On the other hand, a study highlights that older cats are more likely to be infected with FCV than younger cats because the risk of infection is cumulative due to the lifelong nature of infection (Tran et al. 2019). In our study, the age range of cats found positive was 6 to 24 months. Although the exact average age of FCV infection in cats is low, preliminary evidence suggests that young cats may be more susceptible to FCV infection and the shedding rate may increase with age. However, it is clear that studies with larger numbers of cats are needed to show realistic results regarding an association between age and infection.

Studies indicate a strong connection between FCV infection and oral health problems in cats (Zheng et al. 2021). FCV-pos-

itive cats show varying degrees of oral symptoms such as gingivitis, stomatitis and ulceration (Druet et al. 2017). Therefore, it is believed that the likelihood of detecting FCV in cats increases when oral symptoms are present. FCV infection can also lead to chronic gingivostomatitis, which is considered an immune-mediated disease, and in extreme cases to virulent systemic FCV (Hofmann-Lehmann 2022). For example, a study of cats with chronic gingivostomatitis (FCGS) found that decreasing FCV burden significantly correlated with clinical improvement and oro-mucousal ulcer outcomes (Druet et al. 2017). However, it is important to note that the exact mechanism by which FCV contributes to oral cavity disease remains unclear. While FCV has been linked to the development of immune-mediated diseases such as FCGS, the specific molecular interactions between FCV and host cells remain poorly understood. In our study, the data provided suggest various signs of poor oral hygiene in cats, such as loss of appetite, reluctance to perform oral care, gingivitis, stomatitis, and ulceration symptoms. This is consistent with existing literature highlighting the common occurrence of dental disease in cats. A study highlights the need for client education and effective communication by veterinary staff to improve cats' oral health. While brushing teeth is recommended as the most effective method for removing plaque, only a small proportion of cat owners reported using this preventive measure regularly (Oskarsson et al. 2021). Such preventive measures and regular dental care can play a crucial role in helping cats avoid FCV infection, which causes gingivitis and stomatitis. Understanding the connection between FCV and oral disease helps inform prevention strategies and early intervention efforts.

CONCLUSION

It is necessary to provide an up-to-date overview of current diagnostic methods for the detection of FCV in cats with oral lesions, incorporating findings from recent literature and studies. Given the successful and rapid detection of FCV in naturally infected cats with oral lesions, our study provided important insights into understanding its association with disease severity. The high sensitivity, specificity, and potential for field sample testing make RT-PCR a crucial and inevitable method for research and clinical diagnosis related to FCV infection in cats with oral lesions. In summary, we believe we can contribute to the advancement of veterinary practice to improve the diagnosis and treatment of FCV-associated oral diseases in cats.

DECLARATIONS

Ethics Approval

All procedures were approved by the Animal Ethics Committee (AEC) Burdur Mehmet Akif University, Türkiye (No:102/915).

Conflict of Interest

Authors do not have any conflict of interests

Consent for Publication

Not applicable.

Competing Interest

The authors declare that they have no competing interests

Author contribution

Idea, concept and design: HSS, ZE

Data collection and analysis: HSS, ZE

Drafting of the manuscript: HSS

Critical review: HSS

Data Availability

Not applicable.

Acknowledgements

Not applicable.

REFERENCES

- Abd-Eldaim, M. M., Wilkes, R. P., Thomas, K. V., & Kennedy, M. A. (2009). Development and validation of a TaqMan real-time reverse transcription-PCR for rapid detection of feline calicivirus. *Archives of virology*, 154, 555-560.
- Aydin, H., & Timurkan, M. O. (2018). A pilot study on feline astrovirus and feline panleukopenia virus in shelter cats in Erzurum, Turkey. *Rev. Med. Vet*, 169(1/3), 52-57.
- Baydar, E., Eröksüz, Y., Timurkan, M. Ö., & Eröksüz, H. (2014). Feline infectious peritonitis with distinct ocular involvement in a cat in Turkey. *20 (6)*, 961-965
- Binns, S. H., Dawson, S., Speakman, A. J., Cuevas, L.E., Hart, C. A., Gaskell, C. J., ... & Gaskell, R. M. (2000). A study of feline upper respiratory tract disease with reference to prevalence and risk factors for infection with feline calicivirus and feline herpesvirus. *Journal of feline medicine and surgery*, 2(3), 123-133.
- Cao, N., Tang, Z., Zhang, X., Li, W., Li, B., Tian, Y., & Xu, D. (2022). Development and application of a Triplex TaqMan quantitative real-time PCR assay for simultaneous detection of Feline Calicivirus, Feline Parvovirus, and Feline Herpesvirus 1. *Frontiers in Veterinary Science*, 8, 792322.
- Coyne, K. P., Dawson, S., Radford, A. D., Cripps, P. J., Porter, C. J., McCracken, C. M., & Gaskell, R. M. (2006). Long-term analysis of feline calicivirus prevalence and viral shedding patterns in naturally infected colonies of domestic cats. *Veterinary microbiology*, 118(1-2), 12-25.
- Dağalp, S. B., Doğan, F., Farzanî, T. A., Babaoğlu, A. R., Kırmızı, G. A., & Çabalar, M. (2019). Molecular investigation of Feline Herpesvirus 1 (FHV-1) and feline calicivirus in cats with respiratory system problem. *Eurasian Journal of Veterinary Sciences*, 2019, Vol. 35, No. 3, 131-138. <https://doi.org/10.15312/EurasianJVetSci.2019.236>
- Druet, I., & Hennet, P. (2017). Relationship between Feline calicivirus Load, Oral Lesions, and Outcome in Feline Chronic Gingivostomatitis (Caudal Stomatitis): Retrospective Study in 104 Cats. *Frontiers in Veterinary Science*, 2017; 4: 209.
- Fontes, A. C., Vieira, M. C., Oliveira, M., Lourenço, L., Viegas, C., Faísca, P., Seixas, F., Requicha, J. F., & Pires, M. A.

- (2023). Feline calicivirus and natural killer cells: A study of its relationship in chronic gingivostomatitis. *Veterinary World* 16(8): 1708–1713.
- Henzel, A., Brum, M. C. S., Lautert, C., Martins, M., Lovato, L. T., Weiblen, R. (2012). Isolation and identification of feline calicivirus and feline herpesvirus in Southern Brazil. *Brazilian Journal of Microbiology* 43, 560-568. <https://doi.org/10.1590/S1517-83822012000200017>
- Hofmann-Lehmann, R., Hosie, M. J., Hartmann, K., Egberink, H., Truyen, U., Tasker, S., ... & Möstl, K. (2022). Calicivirus infection in cats. *Viruses*, 14(5), 937.
- Karapinar, Z., & Timurkan, M.O. (2024). Heterogeneity of Feline Parvoviruses Genotypes and Determination of Distinct Genetic Lineages in Circulation in Turkey. *Pakistan Journal of Zoology*, 56(2).587-594
- Kim, S. J., Park, Y. H., & Park, K. T. (2020). Development of a novel reverse transcription PCR and its application to field sample testing for feline calicivirus prevalence in healthy stray cats in Korea. *Journal of Veterinary Science*, 21(5).
- Knowles, J. O., Gaskell, R. M., Gaskell, C. J., Harvey, C.E., & Lutz, H. (1989). Prevalence of feline calicivirus, feline leukaemia virus and antibodies to FIV in cats with chronic stomatitis. *The Veterinary Record*, 124(13), 336-338.
- Koc, B. T. & Oguzoglu, T. C. (2020). A phylogenetic study of Feline Immunodeficiency Virus (FIV) among domestic cats in Turkey. *Comparative Immunology, Microbiology and Infectious Diseases*, Dec:73:101544. <https://doi.org/10.1016/j.cimid.2020.101544>
- Lee, Y., Maes, R., Tai, S. H. S. & Hussey, G. S. (2019). Viral replication and innate immunity of feline herpesvirus-1 virulence-associated genes in feline respiratory epithelial cells. *Virus Research* 264, 56-67. <https://doi.org/10.1016/j.virus-res.2019.02.013>
- Lommer, M. J., & Verstraete, F. J. M. (2003). Concurrent oral shedding of feline calicivirus and feline herpesvirus 1 in cats with chronic gingivostomatitis. *Oral microbiology and immunology*, 18(2), 131-134.
- Mochizuki, M., Kawakami, K., Hashimoto, M. & Ishida, T., (2000). Recent epidemiological status of feline upper respiratory infections in Japan. *Journal of Veterinary Medical Science*, 62, 801-803
- Ohe, K., Sakai, S., Sunaga, F., Murakami, M., Kiuchi, A., Fukuyama, M., ... & Taneno A (2006). Detection of feline calicivirus (FCV) from vaccinated cats and phylogenetic analysis of its capsid genes. *Veterinary research communications*, 30(3), 293-305.
- Oskarsson, K., Axelsson, P. L., & Penell, J. C. (2021). Dental Problems and Prophylactic Care in Cats—Knowledge and Perceptions among Swedish Cat Owners and Communication by Veterinary Care Staff. *Animals*, 11(9), 2571.
- Palombieri, A., Sarchese, V., Giordano, M. V., Fruci, P., Crisi, P. E., Aste, G., ... & Di Profio, F. (2022). Detection and Characterization of Feline Calicivirus Associated with Paw and Mouth Disease. *Animals*, 13(1), 65.
- Pedersen, N. C., Sato, R., Foley, J. E., & Poland, A. M. (2004). Common virus infections in cats, before and after being placed in shelters, with emphasis on feline enteric coronavirus. *Journal of feline medicine and surgery*, 6(2), 83-88.
- Radford, A. D., Coyne, K. P., Dawson, S., Porter, C. J., & Gaskell, R. M. (2007). Feline calicivirus. *Veterinary Research*, 2007, 38 (2), pp.319-335.
- Radford, A., Maria A., & Sykes, J. E. (2021). Feline Calicivirus Infections. In: J. E. Sykes (Ed.). *Greene's Infectious Diseases of the Dog and Cat* (pp. 443-454). WB Saunders.
- Schulz, C., Hartmann, K., Mueller, R. S., Helps, C., & Schulz, B. S. (2015). Sampling sites for detection of feline herpesvirus-1, feline calicivirus and *Chlamydia felis* in cats with feline upper respiratory tract disease. *Journal of feline medicine and surgery* 17(12), 1012-1019.
- Sykes, J. E., Browning, G. F., Anderson, G., Studdert, V. P., & Smith, H. V. (1997). Differential sensitivity of culture and the polymerase chain reaction for detection of feline herpesvirus 1 in vaccinated and unvaccinated cats. *Arch Virol* 142(1), 65-74. <https://doi.org/10.1007/s007050050059>.
- Walter J, Foley P, Yason C, Vanderstichel R, & Muckle A. (2020). Prevalence of feline herpesvirus-1, feline calicivirus, *Chlamydia felis*, and *Bordetella bronchiseptica* in a population of shelter cats on Prince Edward Island. *Can J Vet Res* 84(3), 181-188.
- Weeks, M. L., Gallagher, A., & Romero, C. H. (2001) Sequence analysis of feline caliciviruses isolated from the oral cavity of clinically normal domestic cats (*Felis catus*) in Florida. *Research in Veterinary Science* 71:223–225.
- Westman, M. E., Coggins, S. J., van Dorsselaer, M., Norris, J. M., Squires, R. A., Thompson, M., & Malik, R. (2022). Feline immunodeficiency virus (FIV) infection in domestic pet cats in Australia and New Zealand: Guidelines for diagnosis, prevention and management. *Australian Veterinary Journal*. Aug; 100(8): 345–359. <https://doi.org/10.1111/avj.13166>
- Zheng, M., Li, Z., Fu, X., Lv, Q., Yang, Y., & Shi, F. (2021). Prevalence of feline calicivirus and the distribution of serum neutralizing antibody against isolate strains in cats of Hangzhou, China. *Journal of Veterinary Science*, 22(5).

Right aortic arch with megaesophagus in a jack russel dog and diagnosis with contrast fluoroscopy

Yusuf Sinan Şirin¹, Muhammed Yusuf Şirin¹, Mehmet Nur Çetin¹

¹Department of Surgery, Faculty of Veterinary, Burdur Mehmet Akif Ersoy University, Burdur, Türkiye

Key Words:

dog
fluoroscopy
megaesophagus
vascular ring
vomiting

Received : 29 March 2023
Revised : 15 February 2024
Accepted : 21 February 2024
Published : 12 June 2024
Article Code : 1305155

Correspondence:
Y.S. ŞİRİN
(yusuksinan@gmail.com)

ORCID
Y.S. ŞİRİN : 0000-0003-1322-7290
M.Y. ŞİRİN : 0000-0002-7419-5774
M.N. ÇETİN : 0000-0003-2610-8477

ABSTRACT

The material of this case report was a 4-month-old Jack Russel female dog brought to Burdur Mehmet Akif Ersoy University Veterinary Faculty Animal Hospital with the complaint of vomiting. Anamnesis revealed that the patient had chronic vomiting, cough, and respiratory distress following food intake. As a result of examinations, it was determined that the patient had a congenital right aortic arch-type vascular ring anomaly and related megaesophagus. Treatment consisted of a surgical procedure followed by medical therapy. This case report demonstrated that fluoroscopy-guided contrast-enhanced angiography can be used to diagnose vascular ring anomaly.

INTRODUCTION

Vascular ring anomalies occur as a result of abnormal development of the embryonic aortic arches and results in a complete or partial narrowing of these structures in the esophagus and trachea (Follette et al., 2019; Yalçın et al., 2009). In the early stages of fetal life, 6 pairs of aortic arches surround the esophagus and trachea (Yalçın et al., 2009). These six pairs of aortic arches undergo selective involution and reconnect to form great vessels (Follette et al., 2019). If this process works normally, an adult vascular system is formed (Yalçın et al., 2009). The first and second aortic arches degenerate early, but their ventral roots remain as the external carotid arteries. Dorsal roots continue as the distal parts of the internal carotid arteries. The dorsal aortic root of the third arch disappears and the arch becomes the proximal part of the internal carotid arteries. The ventral aortic roots of the third arch elongate and become the right and left common carotid arteries (Ellison, 1980). At the end of the involution of the fourth left aortic arch, it becomes the adult aortic arch. The right 4th aortic arch partially regresses and becomes the right subclavian artery (Follette et al., 2019). Abnormal placement or development of the aortic arches can cause pressure on the organs adjacent to the arches. It is suggested that 0.5-1% of the general population has a congenital heart defect. Approximately 10% of these anomalies are vascular ring formations, of which a permanent right aortic arch is the most common type (Figure 4) (Yalçın et al., 2009).

In this case report, it is aimed to show that vascular ring anomalies can be diagnosed quickly with fluoroscopy.

MATERIALS and METHODS

The material of this case report consisted of a 4-month-old, female Jack Russel dog brought to Burdur Mehmet Akif Ersoy University Veterinary Faculty Animal Hospital with the complaint of vomiting. Anamnesis revealed that the patient had chronic vomiting, cough, and respiratory distress following food intake. It was also informed the dog was smaller than her siblings in size, despite living in the same environment and conditions. On clinical examination, the patient's body temperature was 39.1 °C and had mild dyspnea. Aspiration pneumonia findings were detected on radiography and auscultation. Radiographic examination revealed that the esophagus was dilated in the cranial aspect of the aortic arch, while the trachea was in normal structure and position. Contrast enhanced radiographic examination with barium sulphate did show massive dilated esophageal segment cranial to the base of the heart (Figure 1). In light of all this information, vascular ring was revealed as a suspicious diagnosis. For the definitive diagnosis, angiography was performed by intravenous iohexol via the cephalic vein under the guidance of fluoroscopy, and the patient was found to have a persistent right aortic arch type vascular ring anomaly (Figure 2). An operation was planned for treatment. Following induction with propofol at a dose of 4 mg/kg for patient anaesthesia, the patient was quickly intubated and the anesthesia was maintained with sevoflurane. Prophyl-

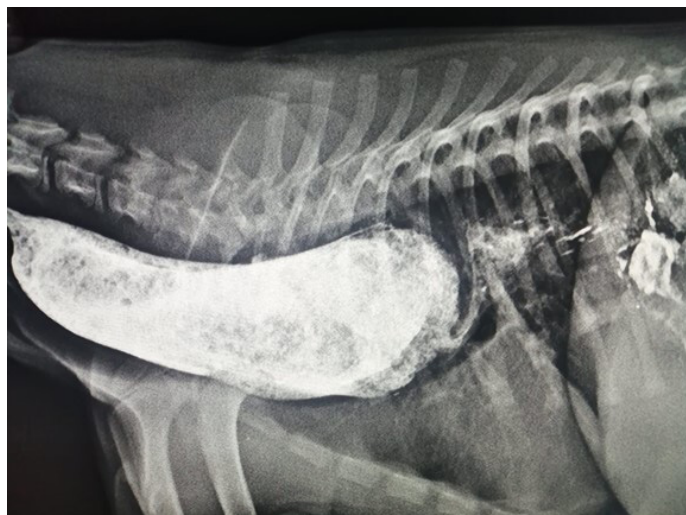

Figure 1. Contrast-enhanced radiography of the megaesophagus

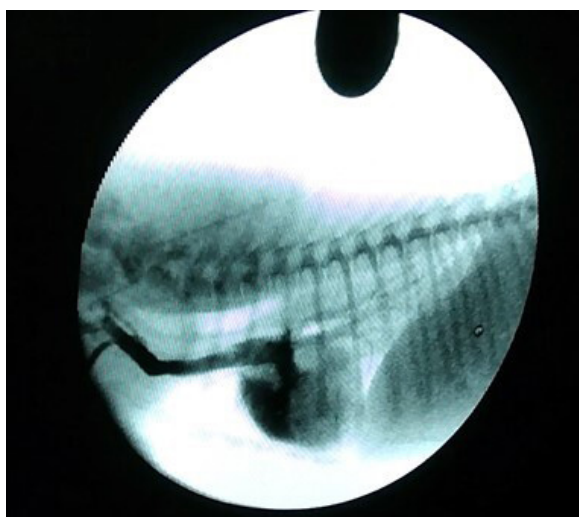


Figure 2. Right aortic arch image on angiography

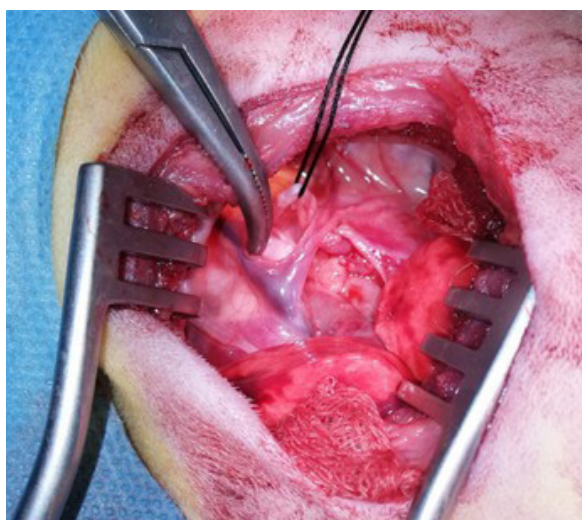


Figure 3. Nervus vagus (separated by suture) and right aortic arch

lactic antibiotherapy with cefazolin was established at a dose of 22 mg/kg intravenous injection. Intraoperative infusion with 0.9% isotonic NaCl at a rate of 5 ml / h was continued as needed. The patient was positioned in right lateral recumbency and related area was prepared for surgery (Follette et al., 2019).

The 4th-5th intercostal thoracotomy incision was performed. The left lung lobes were directed cranially with soaked gauze and the heart was reached. Then, a dilated esophagus and the right aortic arch just above it were detected. Veins (vena cava cranialis and vena cava caudalis) and the vagus nerve around the structure and the nervus accelerans were preserved, and the structure (arch) was separated from other tissues by blunt dissection with mixer right angle hemostat (Figure 3). The structure was dissected in a controlled manner by applying a ligature to the dorsal and ventral ends of the tissue with 3/0 prolene. After making sure that the patient had no signs of hypotension, hypertension, bradycardia, or tachycardia, the operation area was closed and a feeding tube was placed with esophagotomy, and she was awakened. Butorphanol sodium was administered to the patient at a dose of 1 mg/kg for analgesia. The patient was handed over in the postoperative period at the request of the patient's owner. The patient was given furosemide sodium (2-6 mg/kg), cefazolin (22 mg/kg), butorphanol sodium (0.1-1 mg/kg), metoclopramide HCl

its littermates. Multiple other vascular anomalies have also been described that cause esophageal or tracheal compression (Bottorff and Sisson, 2012; Menzel and Distl, 2011). In this case, there was constriction in the esophagus. Regurgitation secondary to esophageal narrowing is a clinical finding that may occur, and this may result in aspiration pneumonia (Bascunan et al., 2020). In this case, compression in the esophagus was thought to cause vomiting and aspiration pneumonia. The diagnosis of is based on signaling, history, clinical signs, physical examination findings, plain and contrast radiography, and endoscopy (Loughin and Marino, 2008). The diagnosis was made using history, clinical symptoms, direct and contrast radiography, and fluoroscopy. Contrast radiographs of the thorax show esophageal dilatation to the heart with constriction at the level of the heart base. In this case, dilatation of the cranial oesophagus was observed on the contrast-enhanced radiograph of the thorax. Surgical treatment is required to eliminate the constriction (Menzel and Distl, 2011). Medical management is insufficient to address the underlying esophageal obstruction (Morgan and Bray, 2019). In this case, surgical treatment was used to relieve the stenosis and was supported by medical treatment. The survival and outcomes of persistent right aortic arch surgery have varied within the previous literature. Survival rates between studies have ranged between approximate-




Figure 4. Permanent right aortic arch and megaesophagus representative image.

E: Esophagus, T: Trachea, A: Aorta, PA: Pulmoner Arter, PRAA: Permanent Right Aortic Arch

(0.2-0.5 mg/kg) supportive medical treatment and follow-up was started.

DISCUSSION

The persistent right aortic arch with a left ligamentum arteriosum or patent ductus arteriosus has been recognised as the most common vascular ring anomalies in the dog, occurring in approximately 95% of cases (Bottorff and Sisson, 2012; Loughin and Marino, 2008; Menzel and Distl, 2011). Epidemiological and breeding studies have shown that German shepherds, Irish Setters and Greyhounds are genetically predisposed to the development of persistent right aortic arch (Gunby et al., 2004; Morgan and Bray, 2019). The material in this case was a Jack Russell with a permanent right aortic arch. Affected dogs can have poor growth compared to littermates (Olson et al., 2021). The affected dog remained smaller than

ly 78% and 94% (Olson et al., 2021). However, it was learnt that after the patient did not continue medical treatment, the patient died due to aspiration after regurgitation.

CONCLUSION

As a result, vascular ring anomalies often affect dogs. In this case report, we tried to provide information on the anomaly of the vascular ring in an affected jack russell dogs. The right permanent aortic arch is the most common vascular ring anomaly. It can negatively affect life by causing symptoms such as developmental delay and vomiting. In general, such patients do not respond to medical treatment. Early diagnosis and early surgical intervention are important in vascular ring anomalies. Early surgical intervention reduces the risk of permanent damage and increases patient survival rates. Fluoroscopy with contrast-enhanced fluoroscopy under mild sedation was sig-

nificantly helpful in the diagnosis of vascular ring anomaly in the patient. Although no other imaging technique was applied to the patient, the location of the anomaly was determined by contrast-enhanced radiography and contrast-enhanced fluoroscopy and the patient was successfully operated.

DECLARATIONS

Ethics Approval

This study does not present any ethical concerns.

Conflict of Interest

The authors declared that there is no conflict of interest.

Consent for Publication

Not applicable.

Author contribution

Idea, concept and design: YYS, MYŞ, MNÇ

Data collection and analysis: YYS, MYŞ, MNÇ

Drafting of the manuscript: YYS, MYŞ, MNÇ

Critical review: YYS, MYŞ, MNÇ

Data Availability

The author has provided the required data availability statement and if applicable, included functional and accurate link to said data therein.

Acknowledgements

Not applicable.

REFERENCES

Bascuñán A, Regier PJ, Case JB, Singh AM, Balsa I, Flander J, Thieman-Mankin K, Ham KM (2020). Vascular ring anomalies in cats. 20 cases (2000-2018), *Veterinary Surgery*, 49(2), 265-273.

Bottorff B, Sisson DD (2012). Hypoplastic aberrant left subclavian artery in a dog with a persistent right aortic arch. *Journal of Veterinary Cardiology*, 14(2), 381-385.

Ellison GW (1980). Vascular ring anomalies in the dog and cat. *Compendium on Continuing Education for the Practising Veterinarian*, 2, 693-705.

Follette CM, Terreros A, Padgett SL (2019). Successful surgical therapy of a double aortic arch in a 10-month-old mixed breed dog. *Case Reports in Veterinary Medicine*, 2019, 1-5.

Gunby JM, Hardie RJ, Bjorling DE (2004). Investigation of the potential heritability of persistent right aortic arch in Greyhounds. *Journal of the American Veterinary Medical Association*, 224(7), 1120-1121.

Loughin CA, Marino DJ (2008). Delayed Primary Surgical Treatment in a Dog With a Persistent Right Aortic Arch. *Journal of the American Animal Hospital Association*, 44(5), 258-261.

Menzel J, Distl O (2011). Unusual vascular ring anomaly associated with a persistent right aortic arch and an aberrant left

subclavian artery in German pinschers. *The Veterinary Journal*, 187(3), 352-355.

Morgan KRS, Bray JP (2019). Current diagnostic tests, surgical treatments, and prognostic indicators for vascular ring anomalies in dogs. *Journal of the American Veterinary Medical Association*, 254(6), 728-733.

Olson NJ, Reems MR, Monnet E (2021). Surgical treatment of persistent right aortic arch with combined ligamentum arteriosum transection and esophageal diverticulum resection in three dogs. *Veterinary Surgery*, 50(5), 1157-1163.

Yalçın E, Çelimli N, Cangül İT, Akkoç A, Yılmaz Z (2009). Vascular ring anomaly associated with right aortic arch in a german shepherd dog. *Turkish Journal of Veterinary and Animal Sciences*, 33(1), 81-84.